

**Nestling mortality in a translocated population of hihi/stitchbirds  
(*Notiomystis cincta*)**

---

A thesis presented in partial fulfilment of the requirements for the degree of  
Master of Science in Conservation Biology  
at Massey University, Palmerston North, New Zealand

---

Rosemary Jane Rippon

2010



*For Dinge who was there,  
For the birds, my raison d'être, and  
For my Dad who shared the passion*



Abstract Nestling mortality in a reintroduced population of the endangered and endemic hihi/stitchbird (*Notiomystis cincta*) was investigated over one breeding season (2008-09) at Zealandia – Karori Sanctuary, New Zealand, to determine whether disease impacted on nestling survival. High rates of both hatching failure (56%) and nestling mortality (39%) in the first clutch made this the least successful breeding season since translocation in 2005. Overall 34% of eggs survived to fledge, compared to 52% and 58% in 2005-06 and 2006-07 respectively. Samples collected from 34 live and 25 dead nestlings were screened for evidence of disease. Bacterial and fungal pathogens were isolated from gastrointestinal swabs but there was no evidence of coccidia or other intestinal parasites in faecal samples. There was no evidence of significant abnormalities in the blood collected from hihi prior to fledging in the haematological parameters tested, and all blood samples were negative for malarial parasites. Tropical fowl mites (*Ornithonyssus bursa*) were found on nestlings and recovered from nest material in very small numbers. Sixty percent of nestling mortality occurred during the first 7 days of life, most often caused by starvation (16%) or poor pulmonary aeration (20%), and death was associated with seasonally low minimum daily temperatures below 11°C. Two older nestlings that died suffered from aspergillosis and an unidentified haemoparasite respectively. Seven nestlings (28%) aged 6-19 days died as a consequence of ventriculitis due to traumatic penetration by insect remnants identified as bee or wasp stings (Hymenoptera). The resulting granulomatous lesions were found in the gizzard mucosa, muscle layers and ventricular or intestinal serosa, and were associated with bacterial and/or yeast secondary infection. It was concluded that hihi may lack the evolutionary adaptations to safely consume introduced bees (*Apis mellifera*) and wasps (*Vespula germanica*, *V. vulgaris*) that are attracted to the feeding stations used to support reintroduced hihi populations. Histopathological examination showed candidiasis contributed to the deaths of four nestlings and *Candida albicans* was isolated from the gastrointestinal swabs of 13 live nestlings from four nest sites, eight of which survived to fledge. The potential of all pathogens may be increased by any cause of temporary or permanent immunosuppression and, in this establishing population, the majority of nestling deaths were associated with environmental conditions (temperature) and ecological factors (introduced prey). It is suggested that ongoing monitoring should include use of temperature data-loggers in hihi nest boxes, health screening of live nestlings, necropsy examination of dead birds, and spore counts to determine environmental levels of *Aspergillus*. Nest box insulation and/or heating could reduce the incidence of hypothermia in nestlings. A review of the carbohydrate provisioning protocols may reduce bee/wasp numbers and minimise the effect of *Candida albicans* at this site.

## **Preface**

---

Throughout this thesis I have used 'hihi', the Maori name, for this endemic bird, in preference to the European common name of 'stitchbird'.

This thesis is formatted as a series of distinct research papers prepared for publication. Because each chapter represents an individual paper, there is some repetition while the format and language for each paper is tailored to the specific requirements of each journal.

Papers written for publication were collaborative works involving Dr Isabel Castro and Associate Professor Maurice Alley, my supervisors for this thesis.

This thesis represents the original work of the author, except where otherwise acknowledged. It has not been submitted previously for a degree at any university.

## **Acknowledgements**

---

This work was made possible thanks to the generous contributions of many people whose input was greatly appreciated. Sample collection was approved by the Massey University Animal Ethics Committee (08/96) and the Department of Conservation (Low Impact Research Permit Number WE/346/RES). Scholarship grants from the New Zealand Wildlife Health Centre Trust Research Fund, Graduate Women Manawatu Charitable Trust and J.P. Skipworth (Ecology) Fund were used to fund some of the work undertaken and contributed greatly to my peace of mind and sanity as I struggled to balance ever-dwindling finances throughout. I thank the trustees and all those involved in administering these funds, your hard work is much appreciated.

To my super supervisors Isabel Castro and Maurice Alley from Massey University, Palmerston North – what can I say? Despite the odds, we made it. Isabel thanks for your enthusiasm and contributions throughout, and for your ability to see the glass half full. I especially thank Maurice for countless hours spent at the microscope and editing the never-ending drafts of these papers, and whose endless patience and encouragement kept me on track. Thank you both for devoting so much of your time and expertise to my project, and for continuing to challenge and inspire me to do better. I do hope there were some redeeming moments for you along the way.

My sincere thanks to Raewyn Empson, Matu Booth, the staff and volunteers of Zealandia – Karori Sanctuary who provided access to the resources and collected samples and data that made this

project a reality. The work would never have gotten off the ground, let alone reached a conclusion without your constant and generous support from beginning to end. Thanks to the volunteers, research workers and Department of Conservation staff, including Rosalie Stamp, Shaarina Boyd and Richard Griffiths, who were involved with managing the hihi populations on Mokoia and Tiritiri Matangi Islands and who submitted samples used in this study.

I am indebted to numerous people who generously gave of their time and knowledge. Ralph Powlesland focussed the planning meeting, Monica Awasthy who shared her expertise in the field, Bruce White and the staff from the Turitea Library who provided a wealth of information. The ectoparasites recovered from nesting material were assessed and identified by Allen Heath and staff at AgResearch Ltd, Wallaceville. My computer gurus, Jamie Munn at Massey, Darin Bailey in Wanganui and George Muscat in WA kept my computer healthy, which in turn kept my head healthy. John Brandon of Canaan Apiaries, Wanganui provided the honey bees and Doug Hopcroft and staff at Manawatu Microscopy and Imaging Centre produced the TEM and SEM photomicrographs that clarified a very grey area. The outstanding technical abilities and expertise of IVAB's staff including Elaine Booker, Evelyn Lupton and Nicola Wallace has been invaluable. Particular mention is worthy of the efforts and input from Ellen Schöner, who found time to support my work in the midst of her own. Cleland Wallace, Tracy Harris, Sharon Tozer, Paul Barrett, Barbara Just, Erica Dahya, Maria Minor and others from the Ecology Group were always willing to help regardless of the request. Alasdair Noble provided much needed help with the minefield that is statistics. Doug Armstrong was responsible for the creative writing that secured much of my scholarship funding and allowed me to concentrate my energies on the important aspects, while the stunning photographs by Paul Gibson and Raewyn Empson illustrate why this work is important. I am grateful for the support and assistance received along the way and feel I have gained many new friends.

Jane Kerridge, friend and colleague, many thanks for the use of laboratory space and resources, and for the constant moral support and many bottles of wine along the way. It worked for me.

Finally, thanks to my Mum, who believed in me from my very beginnings, and to my very special friends and confidants who assured me I was up to the challenge and whose confidence is far greater than I deserve.

Thank you one and all.

## Table of Contents

---

	Page
<b>ABSTRACT</b>	<b>v</b>
<b>PREFACE</b>	<b>vi</b>
<b>ACKNOWLEDGEMENTS</b>	<b>vi</b>
<b>CHAPTER ONE</b>	
<b>Introduction</b>	<b>1</b>
The role of disease in population declines	1
Wildlife disease in New Zealand	3
The New Zealand hihi	5
The role of adaptive management	6
Hihi recovery efforts at Zealandia – Karori Sanctuary	7
Diseases associated with captive and free-living hihi	8
Aims and objectives	11
References	12
<b>CHAPTER TWO</b>	
<b>Diseases affecting a nestling population of free-living of hihi/stitchbird</b>	
<b>(<i>Notiomystis cincta</i>)</b>	<b>17</b>
Abstract	17
Keywords	17
Introduction	17
Materials and methods	18
Monitoring and sampling	18
Histopathology	22
Microbiology	22
Parasitology	23
Haematology	24
Results	25
Nestling age and mortality	25
Pathology	28



Climatic effects and nestling deaths	31
Sample analysis from live nestlings	32
Haematology	32
Microbiology	32
Parasitology	33
Discussion	34
Mortality events	35
Parasites	37
Health parameters in live nestlings	40
Conclusions	41
Acknowledgements	42
References	43

## **CHAPTER THREE**

### **Traumatic ventriculitis following consumption of introduced insect prey (Order Hymenoptera) in hihi/stitchbird (*Notiomystis cincta*)**

<b>nestlings</b>	<b>47</b>
Abstract	47
Keywords	47
Introduction	47
Materials and methods	49
Study population	49
Monitoring and sampling	49
Histopathology	50
Microbiology	50
Electron microscopy	51
Results	52
Nestling mortality	52
Pathology	52
Microbiology	55
Sting morphology	56
Discussion	57
Acknowledgements	63
Literature cited	65

## **CHAPTER FOUR**

### **Candida albicans infection in free-living populations of hihi/stitchbird**

#### **(*Notiomystis cincta*) 69**

Abstract	69
Aim	
Methods	
Results	
Conclusions	
Keywords	69
Introduction	70
Methods	72
Study populations	72
Microbiology	74
Histopathology	75
Results	75
Zealandia – Karori Sanctuary	75
Mokoia Island and Tiritiri Matangi Island	78
Discussion	79
Acknowledgements	84
References	85

## **CHAPTER FIVE**

### **Discussion and conclusions 89**

References	95
------------	----

## Colour Plates

---

		Facing Page
<b>Frontispiece</b>	Seven day old nestlings – Raewyn Empson	iv
<b>Chapter One</b>	Fledgling female – Paul Gibson	xvi
<b>Chapter Two</b>	Ten day old nestlings – Raewyn Empson	16
<b>Chapter Three</b>	Young female – Paul Gibson	46
<b>Chapter Four</b>	Adult male – Paul Gibson	68
<b>Chapter Five</b>	Fourteen day old nestlings – Raewyn Empson	88

## List of Figures

---

	Page
<b>CHAPTER TWO</b>	
Figure 1        Map of Zealandia - Karori Sanctuary showing locations of hihi nest boxes and supplementary feeder stations. The dot on the New Zealand map represents the location of the Sanctuary in the greater Wellington region.	19
Figure 2        a. Hihi nest box; b. Five day old hihi nestlings in nest box; c. Banding 20 day old nestling; d. 20 day old nestling is weighed using a spring balance and open ziplock bag; e and f. Venipuncture of the brachial wing vein of a 20 day old nestling.	21
Figure 3        Distribution of age at death for 25 hihi nestlings that died at Zealandia – Karori Sanctuary during the 2008-09 breeding season.	26
Figure 4        Causes of mortality in 25 hihi nestlings that died at Zealandia – Karori Sanctuary during the 2008-09 breeding season. Number of chicks in each age category (black bars = 1-6 days; white bars = 7 -11 days; and gray bars = 12- 36 days) that died as a consequence of 1 = starvation; 2 = poor lung aeration; 3 = ventriculitis; 4 = other (see Table 2 for details).	26
Figure 5        Photomicrographs of nestling lung tissue (a.) from Chick 42499 showing poor lung aeration and accumulation of proteinaceous fluid in the airways and (b.) from Chick 42843 with ventriculitis and showing good lung aeration. (H&E stain).	29
Figure 6        Photomicrographs of tissue sections from Chick 86437 showing evidence of haemoparasite infection. The protozoa-like organisms can be seen as granular bodies (arrows) resembling merozoites that distend the cytoplasm of (a.) enlarged kidney endothelial cells (Bar = 20µm) and (b.) lung endothelial cells (Bar= 25µm). (H&E stain).	30
Figure 7        Relationship between minimum daily temperature and (a.) chick age at death (b.) cause of death. Whiskers around the mean represent standard errors. (a.) Sample sizes vary between age categories as follows: 10, 8, and 7 respectively. (b.) 1 = starvation; 2 = respiratory failure; 3 = ventriculitis; 4 = other (see Table 2 for details).	31
Figure 8        Average values for nestling PCV in hihi nests at Zealandia – Karori Sanctuary. Numbers indicate individual nests (1= 129, 2= 21, 3= 123, 4= 138, 5=39, 6= 32,	

7= 26, 8= 30, 9= 123a). Number of chicks per nest from left to right = 1, 3, 4, 2, 2, 3, 3, 3, 2.  
Error bars indicate range of results at each nest site. 33

### CHAPTER THREE

Figure 1 Light photomicrograph of a sting remnant within the ventricular mucosa of a hihi nestling (case 42845) showing inflammatory response adjacent to the remnant. Note how the chitinous remnant is tearing out from the surrounding tissue, an artifact of histological processing. H&E stain. Bar=150µm. 54

Figure 2 Photomicrographs showing morphological comparison between an insect remnant within a granulomatous lesion and a honey bee sting cross-section. 54

a. Light photomicrograph showing a sting remnant granuloma within the ventricular muscle wall of a hihi nestling (case 42846). The chitinous sting remnant (S) is surrounded by granulomatous tissue showing discrete bacterial foci (B) of infection. H&E stain. Bar=150µm. b. TEM photomicrograph of the distal end of a sting dissected from *Apis mellifera* showing a cross section very close to the tip. Note the rounded oval shape of the sting-tip cross section. The stylet (St) rails may be seen holding the lancets in place. The two hollow lancets (L) are parted at this point allowing venom to escape the venom canal (VC). Uranyl acetate – lead citrate double stain. Bar=10000nm.

Figure 3 Light photomicrograph showing bacterial infiltration of heart muscle in a hihi nestling (case 42846). Note disruption of the muscle fibers and the bacterial foci within the lesion. H&E stain. Bar=100µm. 55

Figure 4 Light microscopy comparison of an insect remnant within a granulomatous lesion in hihi and honey bee sting apparatus. 56

a. Light photomicrograph of sting remnant located in the liver of a third clutch nestling (case 43078). Note cellular disruption and early inflammatory response in liver cells immediately surrounding the chitinous remnant. H&E stain. Bar=100µm.

b. Light photomicrograph of posterior section of honey bee abdomen showing a slightly oblique cross sectional view of the chitinous sting apparatus. The larger hollow triangular structure is the stylus and the two smaller hollow bean-shaped structures are the lancets. This cross section is distant from the sting tip as the stylus and lancets completely enclose the central venom canal. H&E stain. Bar=100µm.

Figure 5 Scanning Electron Microscope photomicrographs showing similarities in Hymenoptera stings. 58

a. *Vespula germanica* - see stylus rails either side of the lancets. Bar=100µm.

b. *Vespula vulgaris* - see the knife-like barbs of the lancets. Bar=50µm.

c. *Apis mellifera* – see larger barbs on the lancets. Bar=50µm.

Figure 6 Scanning Electron Microscope photomicrographs showing size comparison between the sting shafts (S) and legs (L) of Hymenoptera. 60

a. *Apis mellifera* leg and sting shaft. Bar=2mm.

b. *Vespula vulgaris* leg and sting shaft. Bar=2mm.

c. *Vespula vulgaris* leg (top) and sting shaft. Bar=500µm.

Figure 7 a. Hymenoptera sting mechanism showing how the lancets pull the stylet into the flesh of the victim as venom is injected into the wound. 62

a. sting approaches skin; b. right lancet penetrates and barb holds in position; c. left lancet moves beyond position of right lancet, drawing sting further into tissue; d and e. alternating movements of the lancets draw stylet into flesh and venom is injected.

b. Honey bee (*Apis mellifera*) in the gizzard of a juvenile hihi that died from the effects of envenomation.

## CHAPTER FOUR

Figure 1 Light photomicrograph of the mucosa of the ventriculus of chick C from Karori nestbox 42 showing a severely thickened koilin layer (K) with extensive invasion of *Candida* hyphae that is also infiltrating into the underlying mucosal layer (M). An area of inflammatory response is focussed on necrotic debris in the centre of the section (N). (H&E; bar=100µm) 77

Figure 2 Light photomicrograph of the mucosa of the ventriculus of chick B from Karori nestbox 42 shows blastospores (B) within the koilin layer and extensive invasion of *Candida* hyphae (H) infiltrating into the underlying mucosal layer. (H&E; bar=50µm) 77

Figure 3 Light photomicrograph of a granuloma on the serosal surface of the ventriculus of chick B from Karori nestbox 129 showing budding *Candida* pseudohyphae (C) and an associated insect remnant (S). (Young's fungal stain; bar=50µm) 78

Figure 4 Light photomicrograph of the mucosa of the ventriculus of chick 1 from Mokoia nestbox 60 showing extensive invasion by *Candida* pseudohyphae which are forming yeast-like buds throughout the mucosa. (Young's fungal stain; bar=50µm) 80

## List of Tables

---

	Page
<b>CHAPTER TWO</b>	
Table 1 Productivity for 2008-09 hihi breeding season at Zealandia–Karori Sanctuary	25
Table 2 Cause of mortality and pathology in hihi nestlings at Zealandia–Karori Sanctuary	27
<b>CHAPTER THREE</b>	
Table 1 Lesions associated with ventriculitis in nestlings at Zealandia–Karori Sanctuary	53
<b>CHAPTER FOUR</b>	
Table 1 <i>Candida albicans</i> infection in hihi nestlings at Zealandia–Karori Sanctuary	76
Table 2 Mortalities associated with <i>Candida</i> ventriculitis in nine hihi from Mokoia Island (Mok) and Tiritiri Matangi Island (Tiri) 1996-2002	79





Photo – Raewyn Empson

---

*“The more sophisticated the level of our knowledge is  
The more effective we will be in dealing with the natural world”*

His Holiness the Dalai Lama



Photo – Paul Gibson

## CHAPTER ONE

---

### Introduction

*“Life is fragile, like the dew hanging delicately on the grass,  
Crystal drops that will be carried away on the first morning breeze”*

Dilgo Khyentse Rinpoche





Photo – Raewyn Empson

## CHAPTER TWO

---

### **Diseases affecting a nestling population of free-living hibi/stitchbird (*Notiomystis cincta*)**

*Submitted for publication in the Journal of the Royal Society of New Zealand*



Photo – Paul Gibson

## CHAPTER THREE

---

### **Traumatic ventriculitis following consumption of introduced insect prey (Order Hymenoptera) in hihi/stitchbird (*Notiomystis cincta*) nestlings**

*Submitted for publication in the Journal of Wildlife Diseases*





Photo – Paul Gibson

## CHAPTER FOUR

---

### ***Candida albicans* infection in free-living populations of hihi/stitchbird (*Notiomystis cincta*)**

*Submitted for publication in the New Zealand Veterinary Journal*



Photo – Raewyn Empson

## CHAPTER FIVE

---

### Discussion and conclusions

*“On an evolutionary scale, the species that were most flexible, most adaptable to environmental changes, survived and thrived.*

*A supple mind can help us reconcile the external changes going on all around us”*

Howard C Cutler

# 1 Introduction

---

Conservation effort for species recovery in New Zealand has traditionally focussed on restoration of habitat and the removal of mammalian predators to provide a protected environment for translocated populations of endangered species. Island refuges have become the mainstays for many endemic species under threat of extinction (Saunders and Norton, 2001). Immigration and dispersal may be limited by the island location resulting in closed populations that remain isolated from many external threats and incursions. This has proven to be a successful strategy for endangered species management in New Zealand and the logical progression is towards mainland sanctuaries that will allow novel conservation strategies to be trialled, monitored and refined (Saunders and Norton, 2001). However, because mainland sites are readily accessible, a number of issues must be considered. Predator-free status or year-round predator control is a prerequisite for many endangered species reintroductions. Dispersal to areas outside the sanctuary means individuals may be lost from establishing populations. Accessibility increases the potential for infectious disease to impact on naive populations. Historically, the role diseases have played in New Zealand population declines is largely unknown. Disease processes are dynamic, climate change and anthropogenic factors that appear to be causing a global increase in infectious diseases may pose significant threats to human health, livestock health and wildlife health in the future (Daszak et al., 2000).

## **The role of disease in population declines**

There is growing concern that bottlenecks and low founder numbers may have implications for the survival and persistence of translocated populations under ecological change. There is evidence that small, isolated populations are subjected to a number of pressures leading to loss of genetic diversity, because smaller population size predisposes genetic drift and is associated with inbreeding (Jamieson et al., 2006). Inbreeding reduces reproductive fitness which in turn increases risk of extinction (Frankham et al., 2002). Endangered species typically show less genetic diversity than non-endangered species and genetic diversity is fundamental to adaptive evolutionary change that allows populations to persist where an individual would not survive (Frankham et al., 2002). A decline in genetic diversity is often associated with reduced fitness that reduces the long-term evolutionary potential of the population (Frankham et al., 2002). Maintaining a wide genetic pool is important because all translocated populations must be able to adapt to new and ever changing environments. Recently Hale and Briskie (2007) found that the immune system of birds that had gone through a bottleneck was depressed when compared to that of out-bred populations. This indicates that some endangered species may be more susceptible to disease because their genetic diversity has been reduced (Hale and Briskie, 2007).

Another important factor influencing host susceptibility to disease is stress (Daszak et al., 2000). Stress acts to suppress the immune system thereby increasing host susceptibility to infectious agents (Tompkins and Poulin, 2006). The virulence potential of all pathogens is increased by any cause of temporary or permanent immunosuppression, while opportunist pathogens are generally only able to cause disease when host immunity is compromised. Wildlife species are subject to stress from a variety of sources, both natural and human induced: habitat change; seasonal or permanent climate change; severe weather events; changes in food availability; changes in social systems; existing parasite load or disease processes; captive management; and translocation events (Tompkins and Poulin, 2006). Many of these causes interact and it is necessary to consider underlying factors that may predispose to disease, particularly in populations subject to human interventions. In particular populations of endangered species are often present in what may have been marginal habitat for the species posing a degree of stress from the onset. These species are then translocated to areas that while lacking predators are different and may not be prime habitat either.

The role infectious disease has played in species extinctions is not clear because much of the evidence is anecdotal (Smith et al., 2006). However, parasites and pathogens are implicated in threatened species population declines because reduced immunocompetence in genetically depauperate populations predisposes to disease manifestation (Frankham et al., 2002). The only example where there is evidence that a disease facilitated by human intervention has played a pivotal role in the extinction of endemic species is the case of avian malaria (*Plasmodium relictum*) in Hawaii (Benning et al., 2002). Introduced mosquito vectors and infected poultry together with habitat modification have led to the extinction of nine Hawaiian bird species since the 1900's (van Riper III et al., 1986). Successive waves of human colonisation in the Hawaiian Islands ended the isolation that allowed the evolutionary development of unique species and that served to protect those species (Benning et al., 2002). New Zealand shares this historical situation with Hawaii, having been isolated for many millions of years from other land masses.

The importance of introduced species in driving endemic species extinctions is second only to habitat destruction, and the predator-competitor effect of mammalian species in New Zealand is well-documented. However, the impact of introduced pathogens and parasites is not so well understood nor is the role of the reservoir host. Disease has increased potential to drive a susceptible species to extinction where the pathogen is carried by a second host species (Macdonald and Laurenson, 2006). For example, in Britain the introduced grey squirrel (*Scirius carolinensis*) has largely displaced the native red squirrel (*Scirius vulgaris*) which is now extinct from much of its former habitat (Macdonald and Laurenson, 2006). The decline of the red squirrel was mediated by a virus asymptotically carried in some grey squirrels (Macdonald and Laurenson, 2006). Disease reservoirs are often difficult to identify as the reservoir host may well be a species that is apparently unrelated to, and remote from, the species affected



(Macdonald and Laurenson, 2006). This was the case in Australia, where fruit bats were ultimately found to be the reservoir host of the Henipaviruses that caused mortality in humans and animals during the 1990's (Macdonald and Laurenson, 2006).

There is also concern regarding the relationship between global species loss and the rates at which infectious diseases are emerging (Daszak et al., 2000, Harvell et al., 2002). The factors that facilitate the spread of infectious diseases and disease emergence most frequently result from a change in the ecology of the host or the pathogen, or both (Daszak et al., 2000). Human population expansion appears to be a major factor driving disease emergence (Macdonald and Laurenson, 2006). Increased population density in urban areas is associated with cholera and dengue fever outbreaks, while human populations encroaching on wildlife habitat was a key factor in the global emergence of human immunodeficiency virus (HIV) (Daszak et al., 2000). Ever increasing human encroachment on shrinking wildlife habitat leads to increased wildlife population densities and closer contact between wildlife and domestic species, factors that facilitate infectious disease outbreaks (Daszak et al., 2000). Of conservation concern, canine distemper outbreaks have affected wild populations of African dogs (Daszak et al., 2000) and lions (Harvell et al., 2002) while Marburg and Ebola viruses cause high mortality in captive and wild primates and humans (Daszak et al., 2000).

Weather patterns are implicated in disease outbreak patterns but understanding the effects of climate on disease emergence is difficult (Harvell et al., 2002). However there is evidence that some pathogens and vectors, such as the mosquito vector and arbovirus that cause Ross River fever in humans, are sensitive to climate-driven changes (Harvell et al., 2002). Introduced pathogens that require arthropod vectors may pass through local ticks, mosquitoes and flies to infect endemic species (Tsiodras et al., 2008). In New Zealand, recent deaths of captive mohua or yellowheads (*Mohoua ochrocephala*) were attributed to avian malaria that was most likely transmitted by a local mosquito (Derraik et al., 2008).

### **Wildlife disease in New Zealand**

The main threats to endangered species in New Zealand remain loss of habitat, predation that impacts at all ages and stages of the life cycle, and disease. Infectious diseases can threaten biodiversity, causing rapid population declines that drive species to extinction (Harvell et al., 2002). The factors that may predispose to disease among the endemic species are nearly always human associated, either directly or as interacting factors (Tompkins and Poulin, 2006). Foremost among these are the ongoing effects of habitat destruction and introduced species that, having largely decimated the native flora and fauna on the mainland islands, continue to cause increased disease susceptibility in remnant populations (Tompkins and Poulin, 2006). Because of the long history of isolation, New Zealand wildlife has received relatively limited exposure to disease (Saunders and Norton, 2001) and therefore exotic disease has the

potential for devastating impact on naive endemic populations (Harvell et al., 2002). However, the interactions and range of factors involved are extremely complex and for most free-living populations, disease impacts are not described and are not well understood.

Parasites and disease act to regulate populations and impact on community structure which in turn affects the conservation of endangered species (Sinclair et al., 2006). All animals and birds carry a range of parasites (Sinclair et al., 2006), many of which are host-specific and exist in complex host-parasite relationships where virulence is often inversely related to parasite burden (Atkinson and van Riper III, 1991). Ectoparasites such as mites, lice and ticks are found on the body and feathers and may be site specific as well as being host specific. Endoparasites include the intracellular haemoparasites such as *Plasmodium spp*, *Leucocytozoon spp* and *Babesia spp* that are transmitted via arthropod vectors and the gastrointestinal parasites such as worms, flukes, and coccidia that are most often acquired by ingestion. In New Zealand the effect parasites have on host species survival is largely unknown. The most studied parasites are those that are able to cross species and/or cause disease and mortality in susceptible individuals. Studies of kiwi (*Apteryx spp*) have shown that ticks and other ectoparasites are present on all birds (Pierce et al., 2003). Two haemoparasite species unique to kiwi and thought to be vectored by the kiwi tick (*Ixodes anatus*) were also found. *Babesia kiwiensis* was the cause of a chronic low-grade infection in several birds, while one bird had a concurrent *Hepatozoon* infection (Pierce et al., 2003). Although endoparasites such as coccidia, helminths and nematodes are widely distributed they coexist for long periods within the host species (Sinclair et al., 2006) and while the host must incur some effects, in the absence of other predisposing factors there is evidence to suggest that host nutrition is one of the key factors that may cause sufficient stress for clinical disease to manifest (Sinclair et al., 2006). Parasites such as coccidia are able to cause terminal systemic disease that may be associated with catastrophic population declines, such as occurred in translocated saddlebacks (*Philesturnus carunculatus*) on Motuara Island (Hale, 2008). *Plasmodium spp*, known to be present for several decades in a number of exotic birds (such as the song thrush, blackbird and house sparrow) could be showing increasing prevalence among endemic species (Tompkins and Poulin, 2006), and caused acute malarial infections in a naive saddleback population (Hale, 2008).

Bacterial infections that are associated with normal flora opportunists range from superficial lesions to terminal systemic disease and disease manifestation is dependant on the virulence of the aetiological agent and the immune status of the host. Primary pathogens that may infect immunocompetent hosts to cause morbidity and mortality include: *Salmonella spp* that periodically causes disease outbreaks affecting many species including hihi (Ewen et al., 2007); *Mycobacterium spp* the cause of avian tuberculosis, a disseminated systemic disease commonly seen in waterfowl; *Pasteurella multocida* that causes avian cholera, a meningitis/septicaemia mainly affecting black stilt (*Himantopus novaeseelandiae*), teal (*Anas*

*spp*) and other waterfowl; and *Erysipelothrix rhusiopathiae* an environmental organism that causes acute septicaemia and rapid death in any species infected (M.R. Alley, 2008 pers. comm.).

Numerous viral diseases are known to affect avian species in New Zealand, and there is some evidence that the incidence of viral disease may be increasing (Tompkins and Poulin, 2006). Beak and feather disease is an immunosuppressive disorder caused by a circovirus that affects psittacine birds; Pacheco's disease and inclusion-body hepatitis are caused by herpes viruses that predominantly affect parrots and pigeons respectively (M.R. Alley, 2008 pers. comm.). Avian pox is the most common and important viral disease affecting birds in New Zealand. The virus has worldwide distribution and affects most avian species, presenting in wet and dry forms and causing death directly or indirectly by reducing host immunity and fitness. Transmission may be by arthropod vectors, biting flies, midges and mosquitoes, or by mechanical fomites infecting food or perches etc. Clinical disease has been found in black robins (*Petroica traversi*) (Tompkins and Poulin, 2006), saddlebacks (Hale, 2008) and shore plovers (*Thinornis novaeseelandiae*).

Disease-causing fungi are most often environmental opportunists and disease manifestation is frequently associated with increased numbers or increased pathogenicity of the pathogen, or immunosuppression of the host. This 'disease triangle' may be subject to any number of influencing factors and it is difficult to establish cause and effect in many cases. In New Zealand *Aspergillus spp* spore levels are lowest in undisturbed old growth forest and highest in the modified environments associated with urban development (Perrott, 2001). High spore counts found in regenerating forests (Perrott, 2001) suggest that species susceptible to aspergillosis may be exposed to high spore levels across much of the New Zealand landscape as few areas of pristine forest remain. Aspergillosis most frequently affects birds, including hihi, that forage near the forest floor and environmental spore levels seem to be the most important factor predisposing to disease, although disease manifestation may depend on the immune competency of the host (Perrott, 2001). *Aspergillus fumigatus* is a common cause of secondary pneumonia and airsacculitis in kiwi, particularly where dampness and mould occur (Morgan, 2008).

### **The New Zealand hihi**

Hihi/stitchbirds (*Notiomystis cincta*) are endemic, endangered passerines that were formerly widespread throughout the North Island of New Zealand, but were rapidly extirpated from the mainland following European colonisation (Oliver, 1955). Hihi have been restricted to a single remnant population on Hauturu/Little Barrier Island in the Hauraki Gulf since the 1880's (Oliver, 1955). Hihi are sexually dimorphic, the smaller females are drab olive, while the males display more colourful plumage characterised by a black head with white 'ear' tufts, bright yellow

shoulder coverts and breast band (Higgins et al., 2001). Both sexes show similar white wing bars (Higgins et al., 2001). Cavity-nesting hihi are omnivorous, feeding on a range of invertebrate prey, nectar and forest fruits (Angehr, 1984, Craig et al., 1981, Lovegrove, 1985), and seasonal variations in foraging behaviour reflect food availability throughout the year (Angehr, 1984, Castro, 1995, Lovegrove, 1985, Perrott, 1997). Hihi are very social and the mating system is promiscuous, including extra-pair and forced copulations (Castro, 1995). Males have no input into nest building or incubation, although paired males maintain territories during the breeding season, and may contribute towards provisioning chicks (Castro et al., 2003, Castro et al., 1996). Hihi multiple-clutch and may successfully raise up to three clutches per year (Castro et al., 1996). First clutch eggs are laid in September-October, incubated for three weeks before hatching, and the altricial chicks remain in the nest with parental feeding for a further 28-30 days (Higgins et al., 2001, Low et al., 2007c). Newly fledged hihi have an increased risk of mortality when compared with adult birds (Low and Part, 2009).

The only self-sustaining hihi population is the remnant population on Hauturu (Little Barrier Island) that is thought to number 500-2000 birds (BirdLife International, 2008). Hihi are therefore classified as 'vulnerable' by the International Union for the Conservation of Nature and Natural Resources (IUCN) because of the very small restricted range and small total population (BirdLife International, 2008). While complementing the IUCN classification, the New Zealand Threat Classification system was designed to provide 'a more sensitive classification for taxa with naturally restricted distributions and small numbers as a result of insular rarity' (Townsend et al., 2008). Under this system hihi are classified as 'threatened'. Translocated populations exist on Kapiti Island and Tiritiri Matangi Island and at three mainland sites Zealandia – Karori Sanctuary (KS), Ark in the Park in the Waitakere Ranges and Maungatautiri Wildlife Sanctuary. Despite intensive ongoing conservation effort, the long-term survival of the reintroduced populations is uncertain and all translocated populations are dependent on management strategies that include supplementary feeding, ongoing predator control and periodic top-up translocations (Taylor et al., 2005). Factors limiting the populations vary, and food availability is the only factor that has been experimentally tested and proven to influence population growth (Armstrong et al., 2007, Castro et al., 2003). It is thought that infectious disease may have contributed to the historical decline (Taylor et al., 2005) and disease has been included among the factors considered to limit population establishment at some translocation sites (Taylor et al., 2005, Higgins et al., 2001).

### **The role of adaptive management**

Adaptive management allows ongoing changes and modification to management strategies that reflect the needs of the population and that are determined by ongoing monitoring. Following a number of failed translocation attempts Armstrong et al. (2007) used an adaptive management approach when hihi were translocated to Mokoia Island from Hauturu in 1994. Mokoia (38°06'S,

174°55'E) is a 135ha island situated in Lake Rotorua, a freshwater lake in the central North Island of New Zealand. Eight years of monitoring along with flexible management protocols revealed the importance of supplementary feeding and nest box provision in establishing hihi populations in new habitat areas (Armstrong et al., 2007). Evidence of nest-mites parasitising and causing mortality in nestlings was countered by management strategies that included removing and replacing mite infested nest materials during the brooding period (Armstrong et al., 2007). High mortality rates due to aspergillosis increased mortality rates in adult hihi (Alley et al., 1999) to levels that threatened population viability and ultimately meant the removal of all surviving hihi from Mokoia Island, as it was not possible to control the problem (Armstrong et al., 2007). Forest clearance and subsequent regeneration has created a highly modified forest habitat that is associated with high environmental levels of *Aspergillus fumigatus* spores (Perrott, 2001). Hihi on Mokoia Island were exposed to *Aspergillus fumigatus* spore counts that were much higher than on Hauturu (Perrott, 2001).

Information gained from adaptive management of the Mokoia population has proven to be invaluable in establishing hihi populations elsewhere. No translocated population is currently self-sustaining and ongoing management is required. However, hihi translocated from Hauturu during 1995 and 1996 have established successfully on Tiritiri Matangi island (Armstrong et al., 2002, Low et al., 2007c), and birds from this population are harvested to provide founder stock for new reintroductions (Low and Part, 2009). Tiritiri Matangi (36°36'S, 174°53'E) is a 220-ha island in the Hauraki Gulf 3.5km off the Whangaparoa Peninsula near Auckland in the north of the North Island, New Zealand. Ongoing population monitoring and adaptive management allows hihi at this site year round access to sugar-water feeders and provides nest boxes for breeding (Low and Part, 2009).

### **Hihi recovery efforts at Zealandia – Karori Sanctuary**

Zealandia – Karori Sanctuary (41°17'S, 174°44'E) is an ecologically restored mainland sanctuary situated in suburban Wellington, on the south coast of New Zealand's North Island. The 225ha reserve is surrounded by a mammalian-predator-proof fence and has been subject to an intensive revegetation programme. As the available habitat has grown, the numbers of species inhabiting the reserve have increased, with translocations of rare or threatened endemic fauna aiding this process. Reintroduction of hihi began with the release of 55 juvenile and five adult birds (31 females and 29 males) from Tiritiri Matangi Island in two translocations in February and May 2005 (Empson et al., 2008). During this same period a further four captive bred birds from Mt Bruce were released, with an additional six juvenile and two adult birds released between January and April 2006 (Empson et al., 2008). Management strategies include the provision of food supplements, nest boxes for breeding accommodation, disease surveillance, and monitoring survival and reproductive success rates of the population (Empson et al., 2008). Supplementary feeding with Wombaroo™ Insectivore Mix and/or sugar-water has

been offered since the reintroduction (Empson and Booth, 2009). Hihi responded positively to the translocation with 90% of the birds surviving 5-6 weeks post-release and a small population establishing and breeding annually since (Empson et al., 2008). In the first year post-translocation, nesting began several weeks earlier than recorded elsewhere, resulting in successful fledging of 89 chicks over the first (2005-06) breeding season, an average 5.2 fledglings per pair (Empson et al., 2008).

Despite increasing total population numbers (annual census from September of 2005, 2006 and 2007 yielding 34, 38, 47 hihi respectively) fewer offspring have successfully fledged in subsequent breeding seasons (52% and 58% of eggs fledged in 2005-06 and 2006-07 respectively, decreasing to 34% in 2008-09) (Empson et al., 2008). This appears to be directly related to a change in population dynamics (male hihi numbers have increased, from 46% total population in 2005 to 63% total population in 2008; whilst female numbers have decreased accordingly) along with increased nesting failure rates (47% of nests were successful in 2008-09 versus 69% of nests in previous years) (Empson et al., 2008). The male sex bias may compound the effects, as male aggression and domination are among factors thought to influence female survival and dispersal (Castro et al., 1996). Stress predisposes to disease and it is currently not known whether reductions in female numbers are due to mortality or to dispersal outside the sanctuary area (Empson et al., 2008). Likewise little is known regarding the reasons for nestling mortality and thus nesting failure, but nestling disease has been suggested as a possible cause (Recovery Group Meeting 2007).

### **Diseases associated with captive and free-living hihi**

Nothing is known regarding the incidence of disease in the remnant hihi population on Hauturu, but parasites and pathogens cause morbidity and mortality in hihi at all translocation sites (Taylor et al., 2005). The diseases most commonly contributing to hihi mortality, including those subject to recent research, aspergillosis, coccidiosis (Alley et al., 1999) and parasitic mite infestations (Low et al., 2007c) involve opportunistic pathogens and may be associated with anthropogenic stress factors. Wildlife disease may be facilitated by human activities either directly through environmental change (Epstein, 2001, Harvell et al., 2002) or the introduction of novel pathogens and parasites, or indirectly as induced stress factors (Daszak et al., 2000). For example captive breeding and translocations, which are inherently stressful, are used as management tools in hihi conservation (Taylor et al., 2005) and stress may be cumulative in hihi as is often the case for humans. Likewise, translocations into modified habitats have exposed hihi to increased levels of potential and novel pathogens (Armstrong et al., 2002, Perrott, 2001). During the breeding season intense social interactions, including forced copulation and increased physical attacks and fights (Castro et al., 2004) are energetically costly to both male (Low, 2006a) and female hihi (Low, 2004) and may further stress these birds. Neonates and young are considered to be more at risk from infectious disease because their immune systems

are immature and they may lack appropriate antibody responses to many common pathogens (Toft, 1991, Velasco, 2000). Inbreeding depression and loss of genetic diversity caused by population bottlenecks and the effects of small populations (Frankham et al., 2002, Jamieson, 2009) may also increase disease susceptibility in hihi. Investigations are underway to assess whether population bottlenecks have reduced genetic diversity in hihi and/or caused inbreeding depression (J. Ewen, 2009 pers. comm.). It is thought that inbreeding and erosion of genetic diversity may, in time, impact on the viability of reintroduced populations of this species. The genetic effects on survival and reproduction and how this affects the hihi's ability to cope with environmental change is currently unknown. Preliminary results suggest relatively high levels of genetic diversity in hihi populations when compared to other species that have gone through similar bottlenecks (P. Brekke, Recovery Group Meeting 2009). However, although there is evidence of genetic divergence across the reintroduced populations, genetic diversity within those populations appears reduced (P. Brekke, Recovery Group Meeting 2009).

Since parasites are dependent on host species for their survival, many parasites co-exist with host species in long term relationships that may have developed across evolutionary time frames (Sinclair et al., 2006). However, this is not always the case and hihi are known to suffer morbidity and mortality from a number of parasites. Coccidiosis has been recognised as an important cause of morbidity in juvenile hihi that limited the captive population held at the National Wildlife Centre at Mt Bruce (Pauli, 2000, Twentyman, 2001). Clinical signs include depression, anorexia, weight loss and sudden death (Twentyman, 2001). At necropsy distended loops of the intestine were due to increased intestinal diameter and thickening of the intestinal wall, while hepatic and splenic lesions were also seen in some birds (Twentyman, 2001). Oocysts were also found in free-living hihi from populations on Hauturu (Pauli, 2000), Mokoia and Tiritiri Matangi islands (Twentyman, 2001). The source of infection was most likely adult carriers that occasionally shed high numbers of oocysts (Twentyman, 2001). Ingested oocysts amplify in the gastrointestinal tract and release sporozoites that enter the intestinal mucosa where they produce first and second generation merozoites (Twentyman, 2001). Macrogametocytes are formed and release oocysts, which are shed via the faeces to complete the cycle (Twentyman, 2001). *Capillaria sp* are known to colonise the intestine of hihi, but have not been associated with clinical disease or evidence of histological lesions (M.R. Alley, 2009 pers. comm.) in these birds and therefore the presence of this parasite is not thought to be significant (Cork et al., 1999).

Nest mites predominantly affect nestlings and the tropical fowl mite (*Ornithonyssus bursa*) has global distribution and is a common ectoparasite affecting avian species in New Zealand (Powlesland, 1978). *Ornithonyssus bursa* nest mite infestations limited the Mokoia population during the breeding season (Armstrong et al., 2002) and nestlings on Tiritiri Matangi are subject to ongoing management strategies to control nest mite numbers because parasite-induced mortality is correlated with high levels of infestation at these sites (Armstrong et al., 2007). In a

recent study of the impacts of *Ornithonyssus bursa* on hihi nestlings at Tiritiri Matangi Island, nestling survival and condition at fledging were shown to be reduced by the presence of nest mites (Ewen et al., 2009). Feather loss dermatitis affecting adult hihi on Tiritiri Matangi Island was found to be associated with *Knemidocoptes* mites, a burrowing mite that infests the epidermal layers of the skin to cause pruritic lesions in affected birds (Low et al., 2007b). The lesions irritate the birds causing them to rub and scratch the affected areas, and causes the feather loss (Low et al., 2007b). *Hemialges* sp or feather mites were found to be present on some affected birds (Low et al., 2007b), but these live entirely on the feathers and are not considered to impact to any great degree on the host .

Aspergillosis is a major cause of hihi mortality and a feature of disease establishment is host immunosuppression (Alley et al., 1999). *Aspergillus fumigatus* causes respiratory disease, airsacculitis and pneumonia, in captive and free-living populations of hihi (Cork et al., 1999) that is related to environmental spore levels (Perrott, 2001). The captive population at Mt Bruce is given prophylactic treatment to reduce the incidence of disease when leaf litter is replenished or otherwise disturbed. Environmental monitoring on Mokoia, Tiritiri Matangi and Hauturu islands showed spore counts were highest on Mokoia and lowest on Hauturu (Perrott, 2001). Modified habitat, the result of forest clearance and subsequent regeneration is thought to provide conditions suitable for increased prevalence of *Aspergillus* spp. Mokoia Island has a long history of settlement by Maori and Europeans that included much clearing of the original forest and habitat regeneration is relatively recent (Perrott, 2001). The high incidence of aspergillosis on Mokoia Island increased adult mortality (Alley et al., 1999) to levels that compromised population viability and therefore all surviving birds were removed from the island in 2002 (Armstrong et al., 2007). Candidiasis was noted as a factor associated with the deaths of hihi nestlings on Mokoia Island (M.R. Alley, 2008 pers. comm.) but, due to limited resources, it was not fully investigated. Globally very little work has been done to assess the impacts of candidiasis on wild bird populations (Goodenough and Stallwood, 2010). *Candida albicans* has global distribution as an environmental contaminant and is a commensal inhabitant of the epithelial mucosa and the gastrointestinal tract of many vertebrate species (Velasco, 2000) that is acquired by ingestion (Dahlhausen, 2006). *Candida* infections of the digestive tract are commonly associated with birds in captivity and affect the oesophagus, crop and ventriculus (Velasco, 2000). Crop stasis leads to ill-thrift and emaciation and clinical signs include failure to thrive, regurgitation, and anorexia (Reavill and Schmidt, 2000). Factors that are known to predispose candidiasis often cause immune suppression or disruption to the normal microbial flora; parasitism, malnutrition, Vitamin A deficiency, other infectious diseases, antibiotic therapy, poor hygiene, and stress associated with captivity and overcrowding have all been implicated (Velasco, 2000, Dahlhausen, 2006). Immature nestlings and neonates are more susceptible to *Candida* infections because the immune system is immature, antibody responses are still developing and normal flora may not be well established (Friend, 1999, Toft, 1991, Velasco, 2000).



During February 2006, an outbreak of salmonellosis caused a substantial decline in the hihi population on Tiritiri Matangi Island (Ewen et al., 2007). *Salmonella* Typhimurium DT195 was isolated from freshly dead hihi recovered for necropsy, and is estimated to have killed 26% of the adult hihi in a short, acute disease outbreak on the island (Ewen et al., 2007). This disease outbreak proved to be self-limiting and no evidence has subsequently been found to suggest there is a disease reservoir in existence on the island (Ewen et al., 2007). *Staphylococcus aureus* and *Streptococcus spp* are primary pathogens that cause infections associated with necrotic foci and lesions, while pathogens that have been associated with bacterial septicaemia in hihi include both opportunists such as *Escherichia coli* and primary pathogens such as *Yersinia pseudotuberculosis* (Cork et al., 1999).

Hepatic haemosiderosis is common in captive and free-living hihi, the significance of this is unknown but a genetic predisposition may be associated with this disease (Cork et al., 1999). Sub-lingual oral fistulas are commonly seen in hihi and only recognized at the stage that the tongue hangs below the mandible, having protruded through the floor of the oral cavity (Castro and Taylor, 2001, Low et al., 2007a). This phenomenon seems to occur after fledging but it is not known what predisposes or causes the lesion (Castro and Taylor, 2001, Low et al., 2007a). A captive hihi from Mt Bruce that was found dead without prior symptoms was found to have a honey bee (*Apis mellifera*) lodged in the oesophagus (Alley, 2007). There was no indication that the bee was obstructing the oesophagus, but subsequent investigation showed that the bee had stung and the cause of death was most likely due to envenomation and the effect of toxins on the heart and skeletal muscle tissues (Alley, 2007).

### **Aims and objectives**

Hihi are susceptible to a range of diseases, some of which may be due to anthropogenic influences. The stress factors associated with translocation and ongoing habitat and climate change may further increase disease susceptibility. The factors that influence disease establishment will differ for each site and so it is necessary to monitor the individual populations to determine incidence and prevalence of disease for each population. Recruitment into the KS population during the establishment phase has decreased with time and nestling deaths are increasing. The aim of this study was to investigate diseases and causes of mortality affecting hihi nestlings at KS over a single breeding season (2008-09) with a view to increasing the knowledge base of managers of this and the other translocated populations, as disease has been shown to impact on population viability.

## REFERENCES

- ALLEY, M. R. (2007) An oesophageal bee sting in a hihi, *Notiomystis cincta*. *Kokako*, 14, 41.
- ALLEY, M. R., CASTRO, I. & HUNTER, J. E. B. (1999) Aspergillosis in hihi (*Notiomystis cincta*) on Mokoia Island. *New Zealand Veterinary Journal*, 47, 88-91.
- ANGEHR, G. R. (1984) Ecology and behaviour of the stitchbird with recommendations for management and future research. *Internal Report to the New Zealand Wildlife Services*. Wellington, New Zealand, Department of Internal Affairs.
- ARMSTRONG, D. P., CASTRO, I. & GRIFFITHS, R. (2007) Using adaptive management to determine requirements of re-introduced populations: The case of the New Zealand hihi. *Journal of Applied Ecology*, 44, 953-62.
- ARMSTRONG, D. P., DAVIDSON, R. S., DIMOND, W. J., PERROTT, J. K., CASTRO, I., EWEN, J. G., GRIFFITHS, R. & TAYLOR, J. (2002) Population dynamics of reintroduced forest birds on New Zealand islands. *Journal of Biogeography*, 29, 609-621.
- ATKINSON, C. T. & VAN RIPER III, C. (1991) Pathogenicity and epizootiology of avian haematozoa: *Plasmodium*, *Leucocytozoon* and *Haemoproteus*. IN LOYE, J. E. & ZUK, M. (Eds.) *Bird-Parasite Interactions*. Oxford, UK, Oxford University Press.
- BENNING, T. L., LAPOINTE, D., ATKINSON, C. T. & VITOUSEK, P. M. (2002) Interactions of climate change with biological invasions and land use in the Hawaiian Islands: Modelling the fate of endemic birds using a geographic information system. *PNAS*, 99, 14246-49.
- BIRDLIFE INTERNATIONAL (2008) *Notiomystis cincta*. IUCN 2009. *IUCN Red List of Threatened Species Version 2009.1*. [www.iucnredlist.org](http://www.iucnredlist.org). International Union for Conservation of Nature and Natural Resources
- CASTRO, I. (1995) Behavioural ecology and management of hihi (*Notiomystis cincta*), an endemic New Zealand honeyeater. *Ecology* Palmerston North, New Zealand, Massey University.
- CASTRO, I., BRUNTON, D. H., MASON, K. M., EBERT, B. & GRIFFITHS, R. (2003) Life history traits and food supplementation affect productivity in a translocated population of the endangered hihi (stitchbird, *Notiomystis cincta*). *Biological Conservation*, 114, 271-280.
- CASTRO, I., MASON, K. M., ARMSTRONG, D. P. & LAMBERT, D. M. (2004) Effect of extra-pair paternity on effective population size in a reintroduced population of the endangered hihi, and potential for behavioural management. *Conservation Genetics*, 5, 381-393.
- CASTRO, I., MINOT, E. O., FORDHAM, R. A. & BIRKHEAD, T. R. (1996) Polygyny, face-to-face copulation and sperm competition in the hihi *Notiomystis cincta* (Aves: Meliphagidae). *Ibis*, 138, 765-71.
- CASTRO, I. & TAYLOR, J. (2001) Survival and reproductive success of stitchbird (hihi, *Notiomystis cincta*) suffering from a bill abnormality (oral fistula). *Notornis*, 48, 241-44.
- CORK, S. C., ALLEY, M. R., JOHNSTONE, A. C. & STOCKDALE, P. H. (1999) Aspergillosis and other causes of mortality in the stitchbird in New Zealand. *Journal of Wildlife Diseases*, 35, 481-86.
- CRAIG, J. L., STEWART, A. M. & DOUGLAS, M. E. (1981) The foraging of New Zealand honeyeaters. *New Zealand Journal of Zoology*, 8, 87-91.

- DAHLHAUSEN, R. D. (2006) Implications of mycoses in clinical disorders. IN HARRISON, G. J. & LIGHTFOOT, T. L. (Eds.) *Clinical Avian Medicine*. Palm Beach, Florida, USA, Spix Publishing.
- DASZAK, P., CUNNINGHAM, A. A. & HYATT, A. D. (2000) Emerging infectious diseases of wildlife: Threats to biodiversity and human health. *Science*, 287, 443-9.
- DERRAIK, J. G. B., TOMPKINS, D. M., ALLEY, M. R., HOLDER, P. & ATKINSON, T. (2008) Epidemiology of an avian malaria outbreak in a native bird species (*Mohoua ochrocephala*) in New Zealand. *Journal of the Royal Society of New Zealand*, 38, 237-42.
- EMPSON, R. & BOOTH, M. (2009) Zealandia - Karori Sanctuary Report to Hihi Recovery Group Meeting April 2009. Unpub. <http://www.hihiconservation.com> (accessed 16/11/2009).
- EMPSON, R., GOUDSWAARD, R. & BOOTH, M. (2008) Report on hihi survival and productivity at Karori Sanctuary, 2008. Unpub. <http://www.hihiconservation.com> (accessed 16/11/2009).
- EPSTEIN, P. R. (2001) Climate change and emerging infectious diseases. *Microbes and Infection*, 3, 747-54.
- EWEN, J. G., THOROGOOD, R., BREKKE, P., CASSEY, P., KARADAS, F. & ARMSTRONG, D. P. (2009) Maternally invested carotenoids compensate costly ectoparasitism in the hihi. *Proceedings of the National Academy of Sciences*. The National Academy of Sciences.
- EWEN, J. G., THOROGOOD, R., NICOL, C., ARMSTRONG, D. P. & ALLEY, M. (2007) *Salmonella* Typhimurium in Hihi, New Zealand. *Emerging Infectious Diseases*, 13, 788.
- FRANKHAM, R., BALLOU, J. D. & BRISCOE, D. A. (2002) *Introduction to Conservation Genetics*. , Cambridge, UK, Cambridge University Press.
- FRIEND, M. (1999) Candidiasis. IN FRIEND, M. & FRANSON, J. C. (Eds.) *Field Manual of Wildlife Diseases: General Field Procedures and Diseases of Birds*. Washington DC, USA, U.S. Geological Survey.
- GOODENOUGH, A. & STALLWOOD, B. (2010) Intraspecific variation and interspecific differences in the bacterial and fungal assemblages of Blue Tit (*Cyanistes caeruleus*) and Great Tit (*Parus major*). *Microbial Ecology*, 59, 221-32.
- HALE, K. A. (2008) Disease outbreak amongst South Island saddlebacks (*Philesturnus carunculatus carunculatus*) on Long Island. *Research and Development Series 289*. Wellington, New Zealand, Department of Conservation.
- HALE, K. A. & BRISKIE, J. V. (2007) Decreased immunocompetence in a severely bottlenecked population of an endemic New Zealand bird. *Animal Conservation*, 10, 2-10.
- HARVELL, C. D., MITCHELL, C. E., WARD, J. R., ALTIZER, S., DOBSON, A. P., OSTFELD, R. S. & SAMUEL, M. D. (2002) Climate warming and disease risks for terrestrial and marine biota. *Science*, 296, 2158-2162.
- HIGGINS, P. J., PETER, J. M. & STEELE, W. K. (2001) Stitchbird. IN HIGGINS, P. J., PETER, J. M. & STEELE, W. K. (Eds.) *Handbook of Australian, New Zealand and Antarctic Birds. Volume 5: Tyrant-flycatchers to Chats*. Melbourne, Australia, Oxford University Press.
- JAMIESON, I. G. (2009) Loss of genetic diversity and inbreeding in New Zealand's threatened bird species. *Science for Conservation 293*. Wellington, New Zealand, Department of Conservation.

- JAMIESON, I. G., WALLIS, G. P. & BRISKIE, J. V. (2006) Inbreeding and endangered species management: Is New Zealand out of step with the rest of the world? *Conservation Biology*, 20, 38-47.
- LOVEGROVE, T. (1985) Stitchbirds on Kapiti Island 1983-1985. Wellington, New Zealand, Department of Lands and Survey.
- LOW, M. (2004) Female weight predicts the timing of forced copulation attempts in stitchbirds, *Notiomystis cincta*. *Animal Behaviour*, 68, 637-44.
- LOW, M. (2006a) The energetic cost of mate guarding is correlated with territorial intrusions in the New Zealand stitchbird. *Behavioural Ecology*, 17, 270-76.
- LOW, M., ALLEY, M. R. & MINOT, E. (2007a) Sub-lingual oral fistulas in free-living stitchbirds (*Notiomystis cincta*). *Avian Pathology*, 36, 101-107.
- LOW, M., ALLEY, M. R. & SCOTT, I. (2007b) Pruritic facial dermatitis in a population of free-living stitchbirds. *Journal of Wildlife Diseases*, 43, 262-8.
- LOW, M. & PART, T. (2009) Patterns of mortality for each life-history stage in a population of the endangered New Zealand stitchbird. *Journal of Animal Ecology*.
- LOW, M., PART, T. & FORSLUND, P. (2007c) Age-specific variation in reproduction is largely explained by the timing of territory establishment in the New Zealand stitchbird *Notiomystis cincta*. *Journal of Animal Ecology*, 76, 459-470.
- MACDONALD, D. W. & LAURENSEN, M. K. (2006) Infectious disease: Inextricable linkages between human and ecosystem health. *Biological Conservation*, 131, 143-50.
- MORGAN, K. J. (2008) *Kiwi First Aid and Veterinary Care*, Wellington, NZ, Department of Conservation.
- OLIVER, W. R. B. (1955) *New Zealand Birds*, Wellington, New Zealand, A.H. & A.W. Reed.
- PAULI, J. M. (2000) Diseases of NZ native birds: Disease encountered in captive breeding of the stitchbird and shore plover at the National Wildlife Centre Mt Bruce. *Wildlife Health in Conservation*. Massey University, Palmerston North, Veterinary Continuing Education.
- PERROTT, J. K. (1997) Effects of food supply and competition on the outcome of hihi (*Notiomystis cincta*) translocated to Mokoia Island. *Zoology*. Palmerston North, New Zealand, Massey University.
- PERROTT, J. K. (2001) The ecology of *Aspergillus fumigatus* and implications for wildlife conservation in modified environments. *Wildlife Ecology*. Palmerston North, Massey University.
- PIERCE, M. A., JAKOB-HOFF, R. M. & TWENTYMAN, C. M. (2003) New species of haematozoa from *Apterygidae* in New Zealand. *Journal of Natural History*, 37, 1797-1804.
- POWLESLAND, R. G. (1978) Behaviour of the haematophagous mite *Ornithonyssus bursa* in starling nest boxes in New Zealand. *New Zealand Journal of Zoology*, 5, 395-9.
- REAVILL, D. R. & SCHMIDT, R. E. (2000) Avian Surgical Pathology. IN FUDGE, A. M. (Ed.) *Laboratory Medicine Avian and Exotic Pets*. Philadelphia, Pennsylvania, USA, W. B. Saunders Company.

- SAUNDERS, A. & NORTON, D. A. (2001) Ecological restoration at mainland islands in New Zealand. *Biological Conservation*, 99, 109-119.
- SINCLAIR, A. R. E., FRYXELL, J. M. & CAUGHLEY, G. (2006) Chapter 11: Parasites and pathogens. *Wildlife Ecology, Conservation and Management*. 2nd ed. Carlton, Australia, Blackwell Publishing Ltd.
- SMITH, K. F., SAX, D. E. & LAFFERTY, K. D. (2006) Evidence for the role of infectious disease in species extinction and endangerment. *Conservation Biology*, 20, 1349-57.
- TAYLOR, S., CASTRO, I. & GRIFFITHS, R. (2005) Hihi/Stitchbird (*Notiomystis cincta*) Recovery Plan 2004-2009. *Threatened Species Recovery Plan 54*. Wellington, New Zealand, Department of Conservation.
- TOFT, C. A. (1991) Current theory of host-parasite interactions. IN LOYE, J. E. & ZUK, M. (Eds.) *Bird-Parasite Interactions: Ecology, Evolution and Behaviour*. New York, USA, Oxford University Press.
- TOMPKINS, D. M. & POULIN, R. (2006) Parasites and biological invasions. IN ALLEN, R. B. & LEE, W. G. (Eds.) *Ecological Studies Volume 186: Biological Invasions in New Zealand*. Berlin, Germany, Springer-Verlag.
- TOWNSEND, A., DE LANGE, P., DUFFY, C., MISKELLY, C., MOLLOY, J. & NORTON, D. A. (2008) New Zealand Threat Classification System Manual. IN CONSERVATION, D. O. (Ed.). Wellington, Department of Conservation Science and Technical Publishing.
- TSIODRAS, S., KELESIDIS, T., KELESIDIS, I., BAUCHINGER, U. & FALAGAS, M. E. (2008) Human infections associated with wild birds. *Journal of Infection*, 56, 83-98.
- TWENTYMAN, C. M. (2001) A study of coccidial parasites in the hihi (*Notiomystis cincta*). *Veterinary Science*. Palmerston North, Massey University.
- VAN RIPER III, C., VAN RIPER, S. G., GOFF, M. L. & LAIRD, M. (1986) The epizootiology and ecological significance of malaria in Hawaiian land birds. *Ecological Monographs*, 56, 327-44.
- VELASCO, M. C. (2000) Candidiasis and cryptococcosis in birds. *Seminars in Avian and Exotic Pet Medicine*, 9, 75-81.



## 2 Diseases affecting a nestling population of free-living hihi/stitchbird (*Notiomystis cincta*)

---

**Abstract** Hihi is an endangered New Zealand species and its survival depends on the health of translocated populations. Low nestling survival was detected at Zealandia – Karori Sanctuary (KS) during the 2008-09 breeding season and only thirty four percent of eggs survived to fledge. Samples obtained from live and dead hihi nestlings showed evidence of several disease syndromes which were contributing factors to the nestling deaths. Cause of death was diagnosed by necropsy and histopathology for 25 nestlings. Mortality was highest in young nestlings (<8 days old) and was associated with seasonally low minimum daily temperatures (<11°C). Deaths in this age group were most commonly associated with poor pulmonary aeration and starvation. Ventriculitis caused mortality in 6-19 day old nestlings and there was no indication that weather was implicated. The remaining deaths were due to a variety of unrelated events or causes. *Candida albicans*, *Aspergillus sp* and an unidentified haemoparasite were found among the nestling population. There was no evidence of coccidia or other intestinal parasite infections. In contrast to translocated populations at other sites nesting material recovered from nest boxes contained low densities of *Ornithonyssus bursa*. To improve young nestling survival during inclement weather, extra food provisioning and nest box weather protection for chicks <8 days old is suggested.

**Keywords** disease; mortality; hihi; stitchbird; *Notiomystis cincta*; translocation

### INTRODUCTION

New Zealand has been remote from other centers of evolution and this is reflected in the flora and fauna which consist of a relatively small number of different life forms, unique species and relicts that no longer exist elsewhere. Recent phylogenetic studies of the endangered hihi/stitchbird (*Notiomystis cincta*) suggest this small endemic passerine is taxonomically unique, belonging to a newly formed endemic family, the Notiomystidae (Driskell et al., 2007, Ewen et al., 2006). Formerly widespread across the North Island and some adjacent offshore islands, hihi disappeared from the mainland following European colonisation (Oliver, 1955). Habitat modification and destruction, introduced predators and infectious disease (Alley et al., 1999, Angehr, 1984) have combined to restrict hihi to a single remnant population on Hauturu (Little Barrier Island) since the late 1800's (Oliver, 1955). Hihi recovery efforts have focused on translocations. Currently all reintroduced populations (two on offshore islands and three in mainland sanctuaries) depend on monitoring and management to remain

viable (Taylor et al., 2005). Food availability is the only factor that has been experimentally tested and proven to affect population growth in hihi (Armstrong et al., 2007, Castro et al., 2003) while the ecological factors, such as forest type and maturity, climate, number and types of competitor species present, that limit the long term survival of the reintroduced populations may vary for each site (Armstrong et al., 2002).

Parasites and pathogens cause morbidity and mortality in hihi at all translocation sites (Taylor et al., 2005). Nest mite infestations limited the Mokoia population during the breeding season (Armstrong et al., 2002) and nestlings on Tiritiri Matangi Island are subject to ongoing management strategies to control nest mite numbers (Taylor et al., 2005). Coccidiosis causes sub-clinical infections that may compromise the immune status of individuals when other stress factors are introduced, and has been the cause of deaths of hihi held in captivity (Pauli, 2000, Twentyman, 2001). Aspergillosis causes disease in hihi at all sites but a high incidence on Mokoia Island that increased adult mortality (Alley et al., 1999) meant all surviving birds were removed in 2002 (Armstrong et al., 2007). An outbreak of salmonellosis in February 2006 caused a substantial decline in the hihi population on Tiritiri Matangi Island (Ewen et al., 2007). *Salmonella* Typhimurium DT195, a human strain not described in New Zealand wildlife before, was isolated from dead hihi recovered for necropsy. This bacteria was estimated (mark-recapture and survival probability data) to have killed ca. 26% of the adult hihi in a short, acute disease outbreak (Ewen et al., 2007). Fortunately this disease outbreak proved to be self-limiting and no evidence has subsequently been found to suggest there is a disease reservoir in existence on the island (Ewen et al., 2007). However, this does give an indication of how infectious disease may decimate a naïve population. Disease consequences may be greater in young birds than in adults and, because high mortality in this age group affects recruitment, disease outbreaks may directly affect population viability (Friend and Franson, 1999).

The aim of this study was to investigate the diseases that impact on nestling survival in a reintroduced hihi population.

## **MATERIALS AND METHODS**

### **Monitoring and sampling**

An investigation into causes of nestling mortality was undertaken during the 2008-09 hihi breeding season at Zealandia – Karori Sanctuary (KS) (41°17'S, 174°44'E), a mainland island sanctuary situated in suburban Wellington, on the south coast of New Zealand's North Island (Figure 1). Surrounded by a mammalian-predator-proof fence,



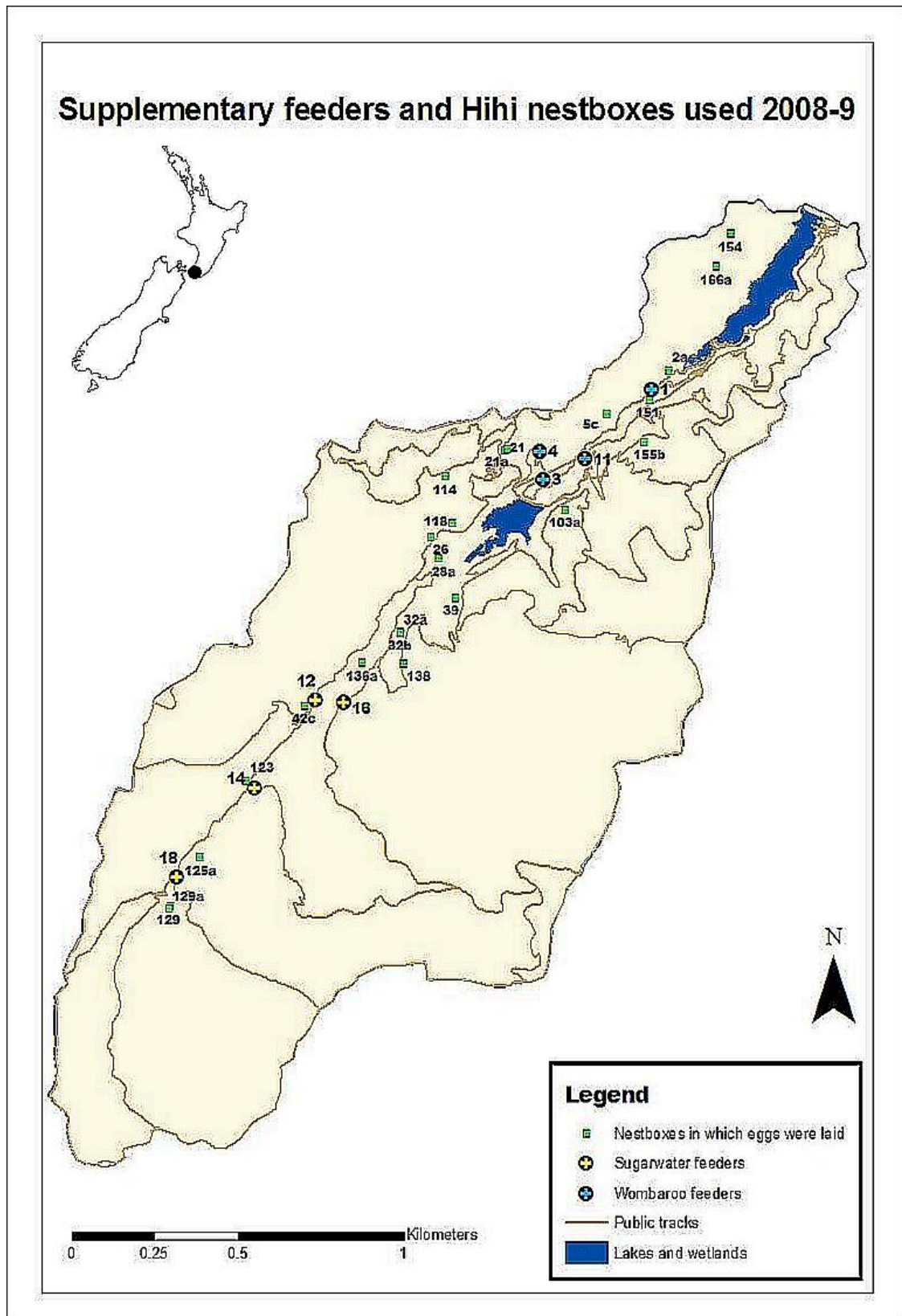


Figure 1 Map of Zealandia - Karori Sanctuary showing locations of hihi nest boxes and supplementary feeder stations. The dot on the New Zealand map represents the location of the Sanctuary in the greater Wellington region.

ecological restoration of this 225ha reserve has increased the available habitat for native species, while translocations of rare or threatened endemic fauna have further increased biodiversity (Lynch, 1995). Reintroduction of hihi began in 2005 with the release of 60 (55 juvenile and 5 adult) birds sourced from Tiritiri Matangi Island (Empson et al., 2008). A similar cohort was released in 2006, with additional smaller hihi introductions over subsequent years (Empson et al., 2008). Management of this population includes colour banding all individuals for monitoring survival and breeding success, as well as provision of nest boxes and supplementary food, in the form of sugar-water and Wombaroo™ Insectivore mix (Empson and Booth, 2009).

During the breeding season male hihi maintain territories and guard their mate during fertile periods (Higgins et al., 2001, Low, 2006a). Hihi rear up to three clutches per year in cavities and female parents take sole responsibility for nest building and incubation while male parents may assist in provisioning the young (Castro et al., 2003, Castro et al., 1996). Nestlings remain in the nest until fledging, a period of 28-30 days (Higgins et al., 2001).

Routine management required that KS staff and volunteers closely monitored the hihi population throughout the breeding season. Data from feeder stations and nest boxes were collected and maintained as the progress for each nesting attempt was recorded from nest building through to fledging. Nest boxes were checked every 2-3 days, and daily during periods of change such as when eggs were due to hatch, or nestlings due to fledge. Further checks were made when sampling was scheduled. All hihi used the nest boxes provided for breeding purposes during 2008-09, allowing ready access to the nest contents. Infertile or abandoned eggs and dead chicks were removed from the nest boxes, encouraging females to nest again. All dead birds recovered were submitted to the New Zealand Wildlife Health Centre (NZWHC) at Massey University, Palmerston North, for necropsy.

Live nestlings were sampled at 5-9 day intervals from hatching until banding at approximately 20 days old (Figure 2). Sampling was carried out by KS staff and the authors. At each sampling, each nestling was weighed in an open ziplock bag using a 100g Pesola spring balance, then faeces and oral swabs were collected, and nests and nestlings examined for the presence of ectoparasites. Faecal samples were collected directly into specimen containers or into plastic bags, but where faeces were not obtained, cloacal swabs were collected. Prior to fledging, nestlings were banded and measured using standard techniques with Vernier calipers to 0.1mm for head-beak and tibio-tarsal lengths, or a stop rule to 1mm for wing and tail lengths (Taylor and Castro, 2000). Venipuncture of the brachial wing vein was used to collect blood samples from the banded nestlings and nest lining samples were also collected.



Photo b – Raewyn Empson

Figure 2 a. Hihi nest box; b. Five day old hihi nestlings in nest box; c. Banding 20 day old nestling; d. 20 day old nestling is weighed using a spring balance and open ziplock bag; e and f. Venipuncture of the brachial wing vein of a 20 day old nestling.

Gastrointestinal (oral and faecal or cloacal) swabs from live or dead nestlings were collected into Amies transport medium for microbiology. As dead nestlings were recovered by KS volunteers and staff, microbiology samples were collected before the carcass was preserved for histopathology. This minimised post mortem changes and reduced the amount of tissue autolysis and bacterial overgrowth that may have occurred had the carcasses been refrigerated or frozen prior to and during transportation. Blood and microbiology samples were held at 4°C during transportation and until testing was completed or the samples were frozen pending further testing. Nest materials were frozen immediately after collection. Sample collection was approved by the Massey University Animal Ethics Committee, Palmerston North (08/96) and the Department of Conservation, Wellington Conservancy (Low Impact Research Permit Number WE/346/RES).

Daily temperature data were obtained from the New Zealand National Institute for Water and Atmospheric Research (NIWA) from the Kelburn weather station. Daily rainfall data at the Karori Reservoir were provided by the Resource Investigations Department of the Greater Wellington Region.

### **Histopathology**

For each of the dead nestlings submitted to NZWHC, cause of death was diagnosed by necropsy examination and histopathology. Dead featherless nestlings were fixed whole in 10% buffered formalin and feathered chicks were incised down the ventral midline to expose the visceral organs before fixation. Following fixation neonates and very small nestlings were cut in 3-5mm transverse sections along the length of the body, so that the whole bird was processed. For larger birds, four to five 3-5mm cross-sections were obtained along the length of the body. Sections were routinely processed and embedded in paraffin blocks from which 5µm sections were cut and stained using haematoxylin and eosin (H&E) staining techniques. The serial cross sections allowed all tissues and organ systems to be systematically examined microscopically. Following initial microscopic examination, further sections were cut to access tissues or lesions deeper in the blocks, or to confirm the presence of bacteria or fungi using Gram-Twort (Twort, 1924) or Young's fungal (Young, 1969) stains.

### **Microbiology**

Oral and faecal or cloacal swabs collected into Amies transport medium (Copan Venturi Transystem™, Amies Agar Gel Medium without Charcoal, Fort Richard Laboratories, New Zealand) were cultured using routine methods for bacterial and fungal isolation (Quinn et al., 1994). Bacterial culture was used to estimate levels of

normal gastrointestinal flora from live and dead birds and to screen for possible pathogens. Columbia 5% Sheep Blood agar (CBA - Fort Richard Laboratories, New Zealand) was inoculated and incubated aerobically at 35°C for three days. Sabouraud's Dextrose agar with antibiotics (SDA - Fort Richard Laboratories, New Zealand) was incubated aerobically at 25°C for 10 days to screen for *Candida spp* and *Aspergillus spp*. Following standard methods, colonies of interest were subcultured onto SDA and CBA for purity and identification by colonial morphology and Gram stain morphology. Diagnostic tests including germ tube production (Quinn et al., 1994) and specific growth characteristics on BBL™ CHROMagar™ Candida agar (Fort Richard, New Zealand) (Hazen and Howell, 2003) were undertaken where necessary.

### **Parasitology**

Assessment for nest mites was made when chicks were removed from the nest for sampling. Nestlings were examined for the presence of mites during the sampling process, with particular attention to areas around the vent or cloaca and eyes, under the bill and wings, between the toes and on the ventral surface of the abdomen (Powlesland, 1976). Mite presence and distribution was recorded, but no action was taken to treat either the nestlings or the nests. Nest boxes were checked for the presence of mites by visual inspection of the walls and lid, and by ruffling the nest cup material for 30 seconds with a bare hand. When present, mites have been found to move onto the skin and may then be counted (Powlesland, 1976). Nest lining samples were collected from 14 nests when chicks were approximately 20 days old. Samples were sealed in plastic containers, and frozen to preserve mites for later identification. Thawed samples were examined for mites, before preserving the entire sample in 95% ethanol for parasite identification. At the conclusion of each nesting attempt, after the nestlings had fledged or earlier if the clutch was abandoned, nests were removed from the nest boxes, a routine management strategy used at KS to minimise nest mite numbers. Eighteen nests were collected into plastic bags and frozen to kill mites for census and identification. Nests were subsequently thawed, dismantled and examined for the presence of nest mites. Mites were preserved in 95% ethanol and submitted with the preserved nest lining samples to Dr Allen Heath, AgResearch Wallaceville, Upper Hutt, New Zealand.

Faecal flotation and examination of faeces for coccidia, capillaria and helminth eggs was performed using standard techniques (Fudge, 2000) for inclusion in a separate study investigating coccidia in New Zealand passerines (E. Schöner, 2010 pers. comm.). Faecal flotation is the method of choice used to recover parasite eggs such as coccidia and small trematode eggs (Hendrix, 1997) commonly found in passerine faecal samples. The preferred method for avian faecal samples at the Institute of



Veterinary, Animal and Biomedical Sciences (IVABS), Massey University was a modified centrifugal method using saturated zinc-sulphate solution (specific gravity 1.35) (E. Schöner, 2010 pers. comm.). Faecal samples were weighed into a sieve and then filtered into a glass tube. Saturated zinc-sulphate solution was added to completely fill the tube and create a positive meniscus (Hendrix, 1997). A square cover slip was applied to the meniscus before centrifuging at 1200rpm for five minutes (Hendrix, 1997). Following centrifugation, the cover slip was removed and placed on a grid slide for microscopic examination at x100 magnification (E. Schöner, 2010 pers. comm.).

Molecular techniques were used to test blood samples (that had been stored frozen) and paraffin embedded tissues for the presence of avian haemoparasites from a nestling that died because histological examination showed evidence of intracellular haemoparasites in the lungs, liver and kidney. Following the manufacturer's instructions, DNA extraction from blood samples and paraffin embedded tissues was carried out using the Qiagen DNeasy™ blood and tissue kit (Qiagen, Valencia CA, USA) (Alley et al., 2008). The DNA obtained was amplified using multiple cycle polymerase chain reactions (PCR) in a 'nested assay, to screen for the presence of *Leucocytozoon spp* alone and for *Plasmodium spp* and *Haemoproteus spp* in combination (Hellgren and Waldenstrom, 2004). The products of PCR were separated by electrophoresis on an agarose gel containing ethidium bromide and visualised on a transilluminator under UV light (Hellgren and Waldenstrom, 2004).

## **Haematology**

A single blood sample was collected from nestlings prior to fledging. Venipuncture sites were swabbed with 70% isopropyl alcohol (Dynarex™ Alcohol Prep Pad, Fort Richard Laboratories, New Zealand) and blood samples (< 150µL) were obtained by puncturing the brachial vein with a 27-gauge hypodermic needle (BD Precision Glide™ Needle, Fort Richard Laboratories, New Zealand) and collecting the blood directly into heparinised microhaematocrit tubes (BD Heparinised Microhaematocrit Tubes, Fort Richard Laboratories, New Zealand) by capillarity. Cotton swabs and pressure were used to halt bleeding, and the nestling was returned to the nest once sampling was complete. Blood films were prepared by the slide drag technique (Fudge, 2000) and air dried at the time of collection. Samples for laboratory processing were stored on ice for transportation and analysed within 8 hours of collection. Blood parameters were assessed using standard techniques (Fudge, 2000). Following the manufacturer's instructions, blood films were fixed in absolute methanol and stained using Dade Behring Diff-Quik™ stains (Global Science, New Zealand) for the assessment of cell morphology, parasite evaluation and differential counts by

microscopic examination (Samour, 2006). Packed cell volume (% PCV) was measured using the microhaematocrit method; microhaematocrit tubes were sealed and centrifuged at 12,000g for 5 min (Heraeus Christ Haemofuge A). A haematocrit reader (Damon/IEC Microcapillary Reader) was used to determine the percentage of whole blood volume that comprises packed red cells. Plasma and cells were separated and frozen pending further investigations.

## RESULTS

Eighty-two eggs hatched and 50 chicks fledged during the 2008-09 breeding season at KS. A total of 32 hihi nestlings died during the study period and 25 (78%) were recovered for necropsy examination; 14 from the first clutch, nine from the second and two from the third. The 22% of nestlings not recovered have been excluded from the data presented because cause of death is unknown. Productivity during the 2008-09 season was reduced because of very high hatching failure rates and nestling deaths that were associated with the first clutch (Table 1), and the breeding season outcomes were poor compared to previous years at this site (34% of eggs survived to fledge versus 52% in 2005-06 and 58% in 2006-07) (Empson and Booth, 2009).

Table 1 Productivity for 2008-09 hihi breeding season at Zealandia – Karori Sanctuary

Clutch Order	Date 1st egg laid	Number of pairs	Number of eggs	Number hatched	Number fledged	% fledged	% nest success
1	07/10/2008	18	72	33	14	19	28
2	17/11/2008	12	51	33	24	47	75
3	06/01/2009	7	23	16	12	52	57

Table adapted from (Empson and Booth, 2009)

### Nestling age and mortality

The cause of death of the 25 hihi nestlings recovered is shown in Table 2. Primary diagnoses have been grouped into four major categories: starvation, unknown with poor lung aeration, ventriculitis and other which includes trauma, sporadic infectious diseases and congenital malformations. Both nestling age and clutch order were found to be associated with the cause of death and Figure 3 gives the age distribution of nestling mortality showing that 60% of the mortality events occurred in nestlings < 7 days old. When the major causes of mortality were plotted against the age groups of the affected chicks there was a marked difference in the frequency of cause of death between the three major nestling age groups (Figure 4).

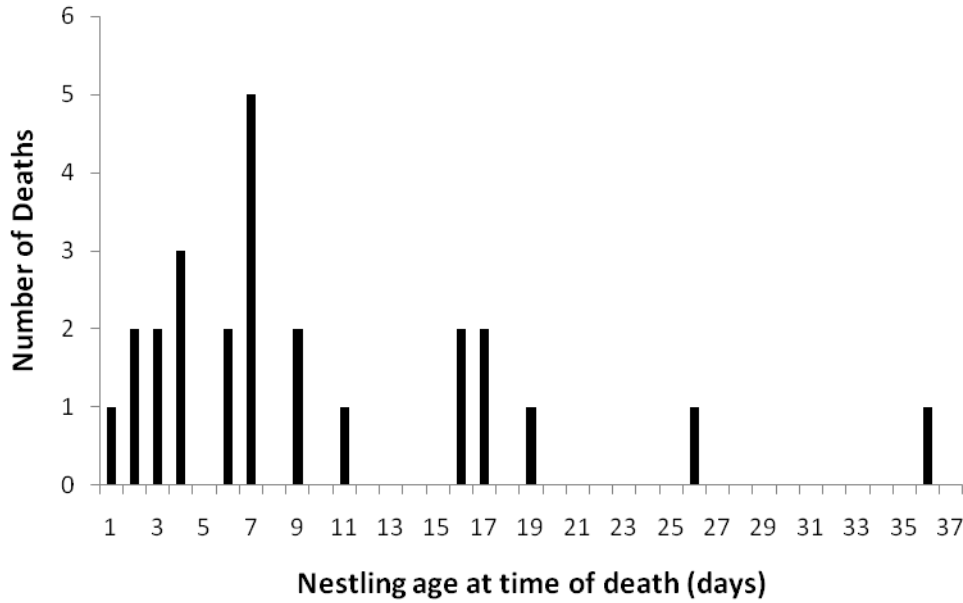

Figure 3 Distribution of age at death for 25 hihi nestlings that died at Zealandia – Karori Sanctuary during the 2008-09 breeding season.

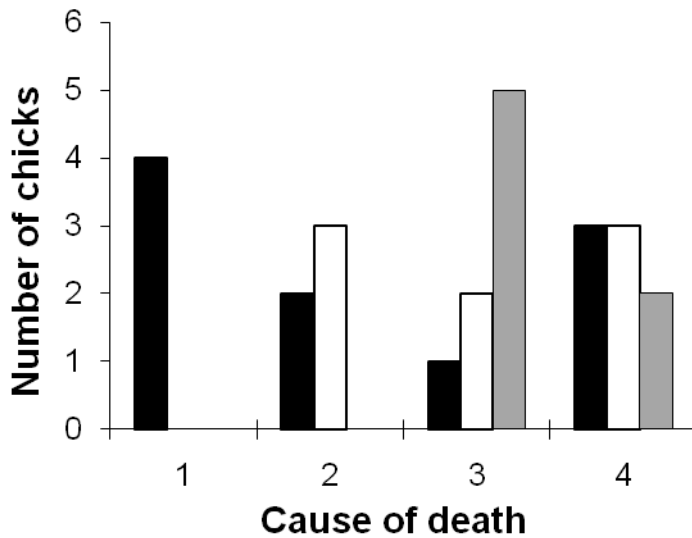


Figure 4 Causes of mortality in 25 hihi nestlings that died at Zealandia – Karori Sanctuary during the 2008-09 breeding season. Number of chicks in each age category (black bars = 1-6 days; white bars = 7 -11 days; and gray bars = 12- 36 days) that died as a consequence of 1 = starvation; 2 = unknown with poor lung aeration; 3 = ventriculitis; 4 = other (see Table 2 for details).

Starvation caused death in 16% of nestlings (2-4 days old) and 24% of nestlings died with poor pulmonary aeration (3 or more days old). First clutch nestlings were



Table 2 Causes of mortality and pathology in hihi nestlings at Zealandia – Karori Sanctuary

Primary Diagnosis	Nest box	Chick ID	Clutch Order	Age*	Date	Secondary/Tertiary Diagnosis
<b>1. STARVATION</b>						
Starvation	154	A	1	2	27-Oct	2. Mandibular cellulitis, mild rhinitis 3. mild omphalitis
Starvation	26	B	1	4	02-Nov	
Starvation	114	B	1	3	04-Nov	
Starvation	129	B	2	2	15-Dec	
<b>2. UNKNOWN with POOR LUNG AERATION (PLA)</b>						
PLA	114	A	1	3	03-Nov	
PLA, anoxia	151	A	1	4	05-Nov	2. Leg trauma - cellulitis
PLA	114	C	1	7	07-Nov	
PLA	114	D	1	7	07-Nov	2. Focal myonecrosis
PLA	21	A	1	6	10-Nov	
PLA (?asphyxia)	28	A	2	11	11-Jan	
<b>3. VENTRICULITIS</b>						
Ventriculitis - severe Candidiasis	42	B	1	7	21-Dec	
Ventriculitis - severe Candidiasis	42	C	1	9	23-Dec	2. Myonecrosis 3. Terminal bacteraemia
Ventriculitis - insect remnants/bacteria	28	B	2	16	16-Jan	2. Myositis / pneumonia - acute bacterial
Ventriculitis - insect remnants	28	C	2	16	16-Jan	2. Myositis / myocarditis / pneumonia - acute bacterial
Acute bacterial myositis	28	D	2	17	17-Jan	2. Terminal bacteraemia 3. Ventriculitis - localised
Acute bacterial septicaemia	28	E	2	17	17-Jan	2. Myositis / myocarditis 3. Ventriculitis - localised
Ventriculitis - focal Candida	129	A	3	6	11-Feb	2. Terminal bacteraemia 3. Proventricular lesion
Peritonitis/hepatitis - Candida/bacteria/insect	129	B	3	19	24-Feb	2. Pharyngitis - bacterial 3. Bronchopneumonia - bacterial
<b>4. OTHER</b>						
Trauma to thorax	26	C	1	9	04-Nov	
Necrotising hepatopathy	151	B	1	7	08-Nov	
Undetermined	151	C	1	7	08-Nov	
Head trauma	166	A	1	4	19-Nov	
Cranial meningocoele	129	A	2	1	14-Dec	
Mycotic bronchiectasis / pneumonia	21	C86428	2	36	18-Jan	
Avian haemoparasite	138	C86437	2	26	16-Feb	2. Renal failure / nephrosis

\*age = days after hatching. C = band identification number of nestling. ? = findings not conclusive.

particularly affected by starvation and poor lung aeration (57% of deaths; three deaths from starvation and five with poor lung aeration). In contrast, starvation and poor pulmonary aeration were each associated with the death of a single nestling from the second clutch and none from the third. Ventriculitis lesions were found in 32% of the nestlings examined, and there was concurrent evidence of dietary insect remnant

penetration in three of the four nestlings (Rippon et al., Chapter 3 submitted). Deaths in this category affected 6-19 day old nestlings at a single nest from each of the three clutch orders. Mortality for the remaining 28% of nestlings was due to a variety of causes (Table 2). In nestlings less than 7 days old there was one case of necrotising hepatopathy, one death was due to a congenital abnormality (cranial meningocele), and cause of death for the remaining nestling was undetermined. Two older nestlings died at or after fledging; one 26 day old chick showed lesions consistent with avian haemoparasitism while the other succumbed to aspergillosis at 36 days of age.

## **Pathology**

Starvation was diagnosed in nestlings that showed little or no fat reserves in subcutaneous tissues due to utilization of the fat stores, in conjunction with no, or very little, ingesta present in the gastrointestinal tract. Where yolk sacs were found, these were also depleted. Chicks with poor lung aeration and no other findings were placed in a category of 'Unknown with poor lung aeration'. These chicks had evidence of total or partial airway collapse (bronchi and parabronchi) indicating that the chick was not breathing adequately at the time of death. Congestion and haemorrhage was frequently observed associated with lung collapse and the presence of proteinaceous fluid (Figure 5a) in the airways. Occasionally fibrin, sloughed epithelial cells, macrophages and small amounts of aspirated debris were found in conjunction with the proteinaceous fluid. In one case there was trauma associated with the fluid accumulation, but in most cases there was no evidence of underlying systemic disease or trauma.

Histopathological lesions consistent with a bacteraemia were seen in seven nestlings. These consisted of multifocal lesions of acute inflammatory necrosis involving skeletal muscle, myocardium, liver, spleen and occasionally the kidney. A few heterophils, which were sometimes necrotic, surrounded clumps of Gram-negative bacteria present within blood vessels, endothelial cells or necrotic myocytes. All these cases showed evidence of traumatic ventriculitis associated with insect sting penetration (Rippon et al., Chapter 3 submitted).

A 26 day old nestling died with renal failure and nephrosis associated with an unidentified avian haemoparasite. The protozoal organisms were present in hepatocytes, kidney cells, and liver and lung endothelial cells (Figure 6) and resembled *Plasmodium spp*, the causative organism of avian malaria; although blood film examination and PCR analysis of frozen blood and fixed tissues from this bird failed to identify the organism. Mycotic bronchiectasis and pneumonia caused the death of a 36 day old nestling. The nature of the lesions produced and the morphology

of the fungal hyphae were consistent with those seen previously in cases of aspergillosis in adult hihi (Alley et al., 1999).

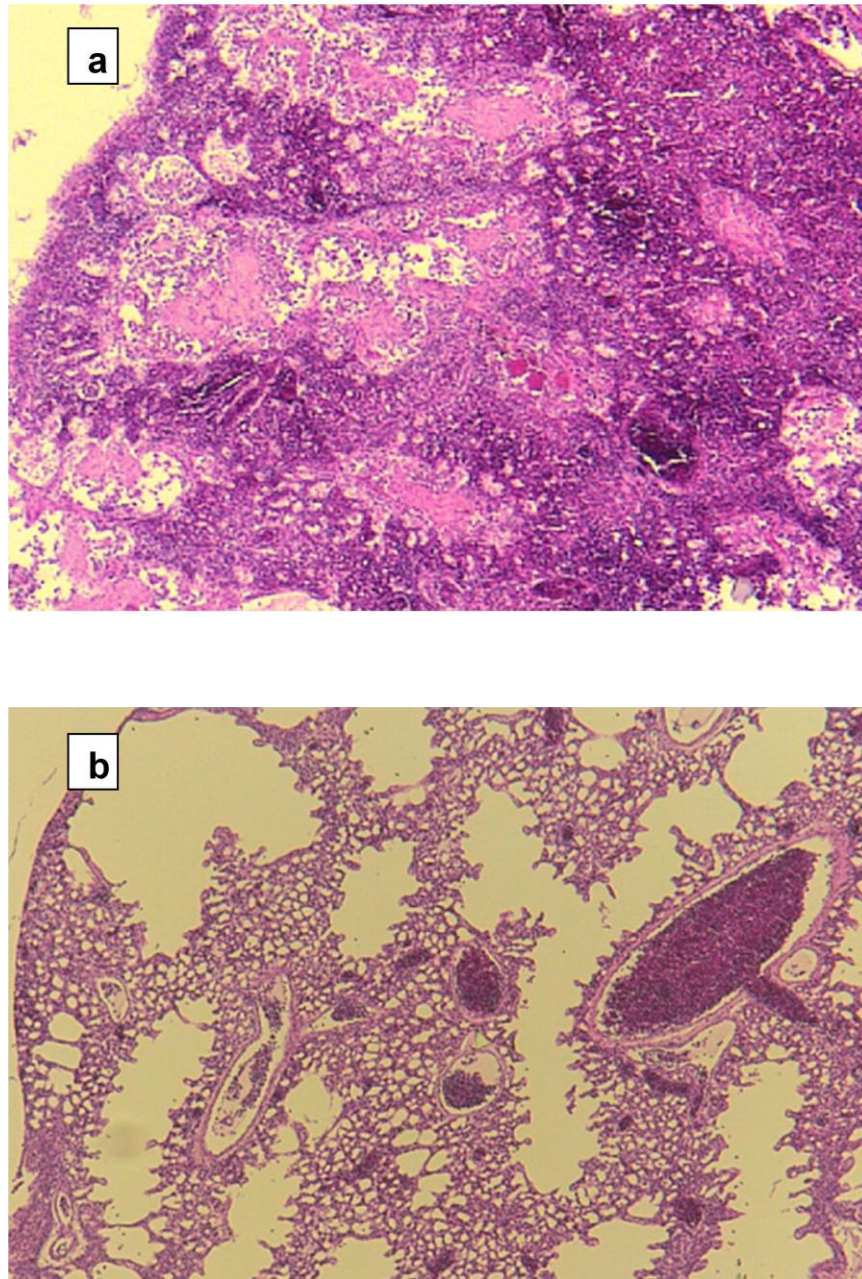


Figure 5 Photomicrographs of nestling lung tissue (a.) from Chick 42499 showing poor lung aeration and accumulation of proteinaceous fluid in the airways and (b.) from Chick 42843 with ventriculitis and showing good lung aeration. (H&E stain).

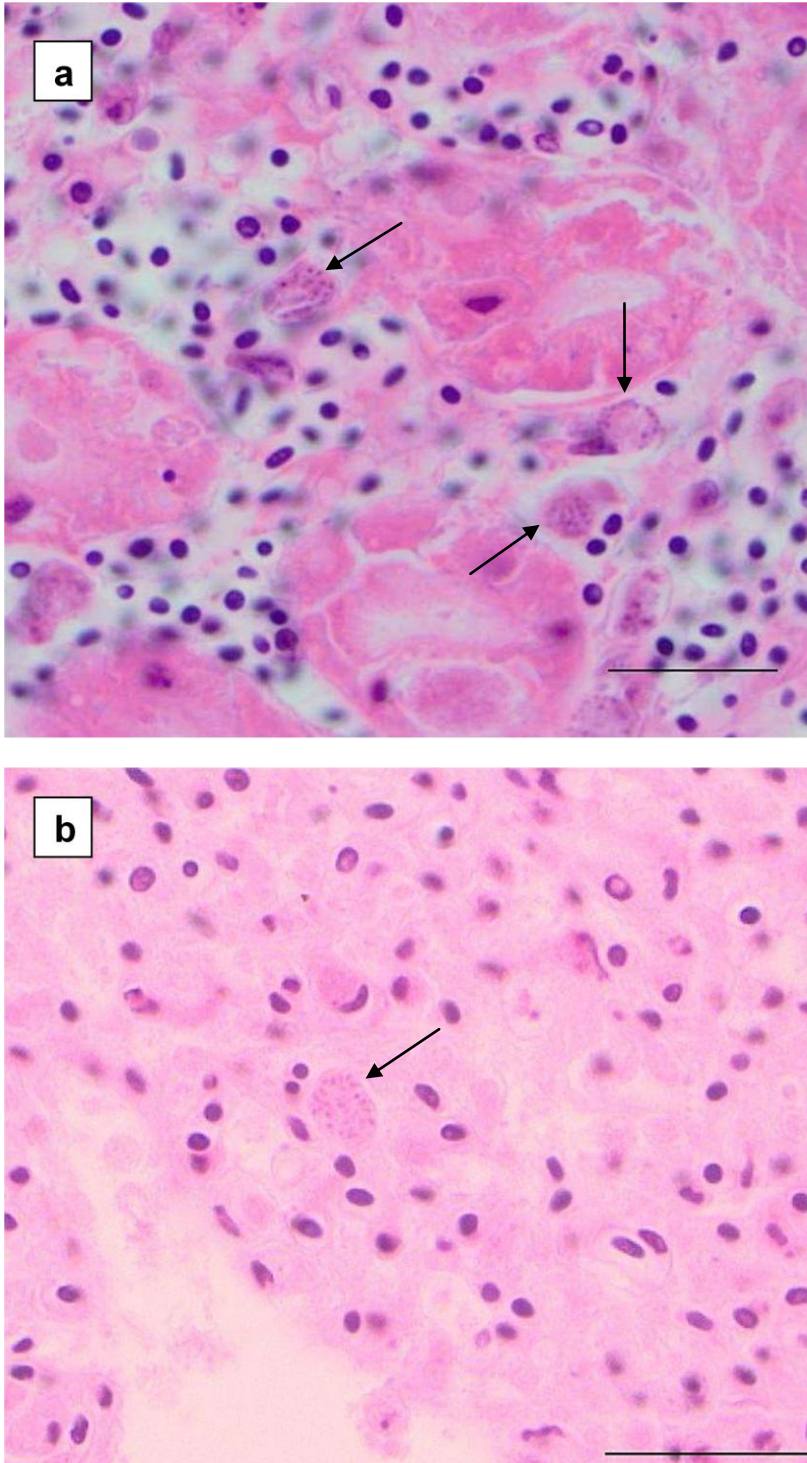


Figure 6 Photomicrographs of tissue sections from Chick 86437 showing evidence of haemoparasite infection. The protozoa-like organisms can be seen as granular bodies (arrows) resembling merozoites that distend the cytoplasm of (a.) enlarged kidney endothelial cells (Bar=20 $\mu$ m) and (b.) lung endothelial cells (Bar=25 $\mu$ m). (H&E stain).



### Climatic effects and nestling deaths

Clusters of nestling deaths were significantly associated with daily minimum temperatures between 4-11°C (Figure 7a; ANOVA  $F = 11.73$ ;  $df = 2$ ;  $P = 0.0003$ ; significant differences between groups 1 and 2 versus 3  $LSD < 0.05$ ). For example, intermittent unseasonal temperatures below 11°C from 26 October – 31 December affected nestlings up to 7 days old at six nest boxes during the first and second clutches. During this period hypothermia was associated with the deaths of 11 nestlings; five from respiratory failure, four from starvation, and one each from necrotising hepatopathy and unknown causes. The other causes of death in nestlings during this time included ventriculitis and trauma; however these deaths were not associated with specific weather events and/or occurred in older nestlings (Figure 7b; ANOVA,  $F = 2.64$ ;  $df = 3$ ;  $P = 0.076$ ). Infectious diseases caused the deaths of two older chicks and these deaths were not associated with low temperatures (Figure 7a).

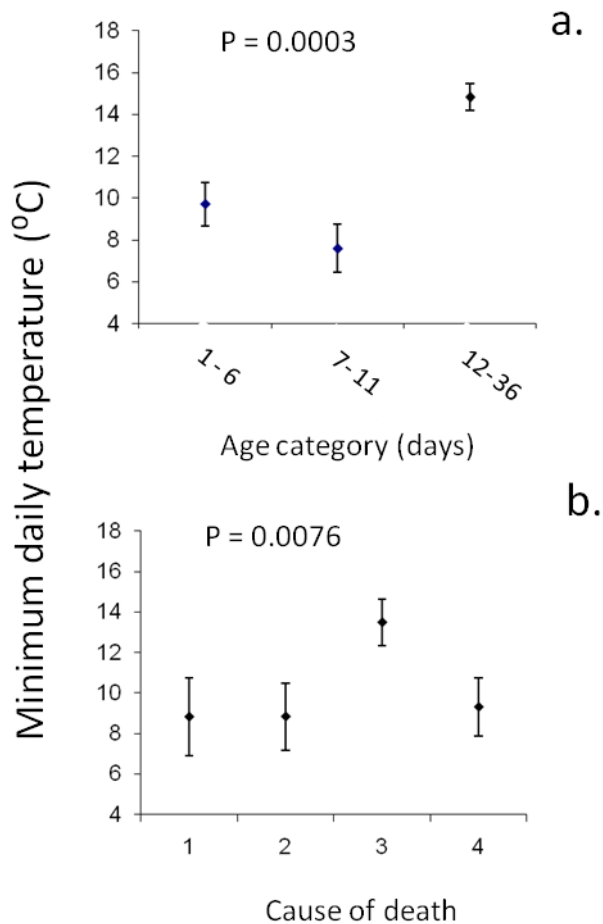


Figure 7 Relationship between minimum daily temperature and (a.) chick age at death (b.) cause of death. Whiskers around the mean represent standard errors. (a.) Sample sizes vary between age categories as follows: 10, 8, and 7 respectively. (b.) 1 = starvation; 2 = respiratory failure; 3 = ventriculitis; 4 = other (see Table 2 for details).

## **Sample analysis from live nestlings**

The majority of hatching failures and nestling deaths occurred in the first clutch but no live nestlings were sampled during this period. Sampling of live nestlings began in December 2008 and 34 nestlings from 11 nests were sampled before the final chicks fledged in March 2009.

## **Haematology**

The measured PCV results for the 23 blood samples collected from 18-26 day old nestlings at nine nest sites followed a normal distribution (Anderson-Darling A-squared 9.38;  $P = .0377$ ). Results ranged from 23-39%, with mean PCV of 31% (95% confidence interval 28.8-32.9). There was little evidence of correlation within age groups for PCV (Pearson Correlation PCV and age = 0.188;  $P = 0.391$ ), or between nestling weight and PCV (Pearson Correlation PCV and weight = -0.249;  $P = 0.251$ ). Siblings from individual nest sites showed a significant correlation in PCV values (Figure 8. Kruskal-Wallis Test  $H = 20.23$ ;  $df = 8$ ;  $P = 0.010$ ; adjusted for ties). The PCV was higher (PCV >30%) in the second clutch nestlings when compared to third clutch nestlings (PCV <30%; Figure 8). However, the very small sample size limits the conclusions that can be made.

It was not possible to draw firm conclusions following microscopic examination of the blood films. Red cell appearance was essentially normal, with increased numbers of immature cells present (seen as moderate to many polychromatic red blood cells) indicating active haemopoiesis in these young birds (Samour, 2006). Thrombocytes were plentiful and morphologically normal (Samour, 2006). White cells appeared morphologically normal (after Samour 2006, pp 600-604) (Samour, 2006). All samples were collected immediately prior to fledging, and with two known exceptions, all the birds tested were well enough to fledge. Variations were noted in the differential counts but the lack of clinical information prevented diagnostic interpretation of the changes. Blood parasites were not seen in any of the films examined despite histological evidence that a haemoparasite may have been implicated in the death of one nestling (see also parasitology results below).

## **Microbiology**

Gastrointestinal swabs were collected from 59 nestlings (34 live nestlings at 11 nest boxes and 25 dead nestlings at 12 nest boxes) and processed to compare the normal flora and to look for potential pathogens. Aerobic culture showed the oral flora comprised predominantly Gram-positive organisms that included various

*Staphylococcus spp*, *Streptococcus spp*, and *Corynebacteria*. Faecal and cloacal flora comprised Gram-positive cocci, mainly faecal *Streptococci*, and varying numbers of Gram-negative bacilli, predominantly coliforms. Swabs taken from dead birds showed increased numbers (colony forming units) of coliforms present at both sites demonstrating that these opportunists are capable of rapid post-mortem proliferation. Although yeasts were commonly isolated from the gastrointestinal swabs of live and dead nestlings, *Candida albicans* was isolated from nestlings at four nest boxes only (Rippon et al., Chapter 4 submitted). *Candida albicans* was associated with ventriculitis in the nestlings that died, but eight chicks colonised with *Candida albicans* survived to fledge. *Aspergillus spp* is primarily a pathogen of the respiratory system and was not isolated from the gastrointestinal swabs collected.

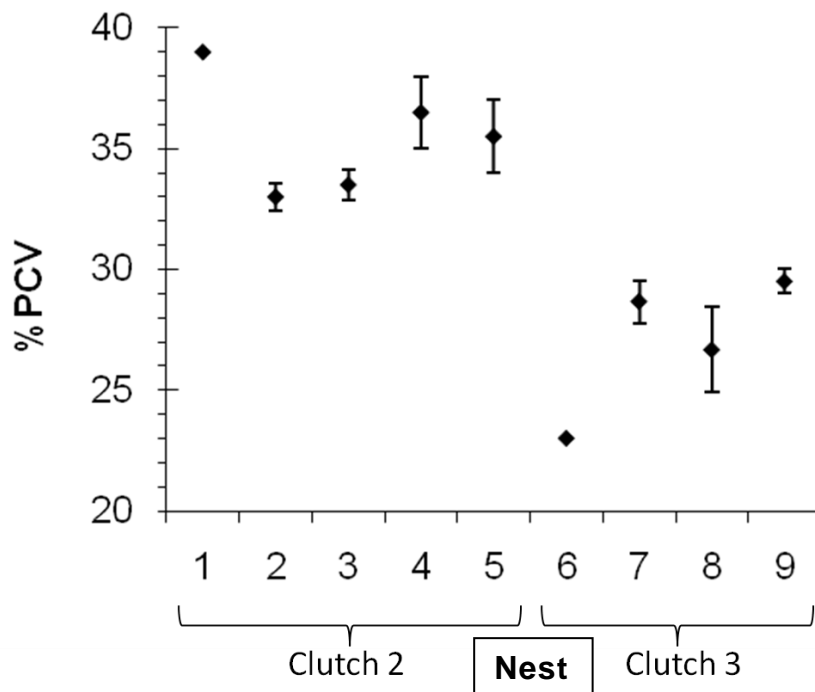


Figure 8 Average values for nestling PCV in hihi nests at Zealandia – Karori Sanctuary. Numbers indicate individual nests (1= 129, 2= 21, 3= 123, 4= 138, 5=39, 6= 32, 7= 26, 8= 30, 9= 123a). Number of chicks per nest from left to right = 1, 3, 4, 2, 2, 3, 3, 3, 2. Error bars indicate range of results at each nest site.

### Parasitology

Mites were detected on nestlings from two nest boxes. Very few mites (< 5) were seen per nestling and mites were not found on all siblings from a given nest box. Nest mites were not seen during visual inspections of the nest boxes and were not detected by ruffling the nest lining material. However, detailed examination of nest materials removed from the nest boxes revealed the presence of nest mites, *Ornithonyssus*

*bursa*, in 14 of 18 nests examined (0-ca.150 mites/nest) and 12 of 14 nest lining samples (0-31/sample). An unidentified feather mite, *Hemialges sp*, was found in seven of the nests (0-18 mites/nest/sample), and in a single nest only one free-living mite and one feather louse, *Mallophaga sp*, were also found. Two of the nests examined were negative for ectoparasites, four nestlings successfully fledged from the first while the second was a nest from which all eggs failed and had been removed prior to collecting the nest material.

There was no evidence of haemoparasites in any of the blood films examined and it is possible that parasites sequestered in the tissue phase of the life cycle may not have been released into the bloodstream (Pierce, 2000). Blood film examination for malarial parasites is mainly used to detect and identify blood parasites in acute phases of infection (Jarvi et al., 2002) because, due to low recovery rates, this method is unlikely to detect chronic and low grade infections.

PCR analysis for avian haemoparasites (*Plasmodium spp*, *Haemoproteus spp* and *Leucocytozoon spp*) was performed on blood that had been collected and frozen, and also on the fixed, wax embedded tissues from the hihi nestling suspected to have a haemoparasite infection on histological examination, with negative results. The reasons for the negative PCR results are unknown. The sensitivity and specificity of this technique may vary considerably as it is dependent on successful amplification, the sequence selected for amplification and the primers used.

Faecal samples were collected from 31 live nestlings aged 5 - 23 days. Faeces were examined for the presence of ova, cysts and parasites including coccidia, capillaria and other helminthes. All faecal samples examined by centrifugal flotation weighed less than 0.1g and were negative for intestinal parasites. Similarly, there was no evidence of coccidia infection in any of the dead nestlings examined.

## **DISCUSSION**

In this investigation, dead nestlings and samples from live nestlings were collected with a view to screening for the possible presence of disease causing processes. It was necessary to limit sample collection from live nestlings in order to cause minimal stress and disruption to them and their parents. For these reasons, gastrointestinal swabs and faecal samples were collected on up to three occasions and blood sampling was performed prior to fledging only. In the case of dead nestlings, similar swab samples were used so that comparisons could be made between live and dead nestlings. Carcasses were preserved in formalin immediately following collection of the microbiology samples, and while this restricted the information regarding



infectious pathogens present, the tissues were well preserved for histopathology. Since there was little information regarding disease prevalence at this site, this compromise was agreed upon.

### **Mortality events**

Altricial nestlings are susceptible to parasites and disease (Morrison et al., 2009) as well as environmental effects such as temperature (Dawson et al., 2005) because much of their physiological development occurs after hatching. These findings support those of Low and Part, 2009 who found that the survival probability for hihi nestlings on Tiritiri Matangi Island increased over time and that younger nestlings are more likely to die than older nestlings. In addition nestling age was found to be associated with specific mortality events. The deaths in nestlings up to 7 days of age that accounted for 60% of the nestling mortality were mainly due to starvation or associated with poor pulmonary aeration that were both linked with climatic events that resulted in daily minimum temperatures less than 11°C. Weather events may have predisposed to other deaths in neonates by further stressing already ailing birds. Nestlings aged 6-19 days from all three clutch orders apparently died from sequelae relating to ventriculitis lesions (Rippon et al., Chapter 3 submitted) but no evidence was found that these deaths were temperature-related. Similarly, deaths that were attributed to infectious diseases such as aspergillosis (36 day old) and an unidentified avian haemoparasite (26 day old) did not appear to be correlated with minimum temperature.

Poorly developed anatomical and physiological thermoregulation in altricial nestlings means young nestlings are vulnerable to external temperature fluctuations (Dawson et al., 2005) and may succumb to hyper- or hypothermia (Mertens, 1977). Signs of thermoregulation in altricial birds are first seen at 4-6 days old and nestlings up to 7 days old may suffer hypothermia when the parents are away from the nest for prolonged periods (Mertens, 1977, Pereyra and Morton, 2001). The range of temperature tolerance is determined by the thermal properties of the nest and some biological and life history traits (Mertens, 1977). For example, the materials, construction and location of the nest (i.e. an open nest or a nest within a cavity) will determine the range of temperatures which nestlings will be exposed to. Life history traits such as brood size, nestling age and body weight will influence the response to temperatures (Mertens, 1977). It was found that daily minimum temperatures below 11°C were linked to mortality events affecting nestlings up to 7 days old, indicating that hypothermia was limiting nestling survival at KS. Dawson et al., 2005 showed experimentally that in cool temperate zones increasing the nest temperature by approximately 5°C was positively correlated with nestling survival, increased body

mass and faster growth rates in nestling tree swallows (*Tachycineta bicolor*). Therefore, the low daily minimum temperatures at KS that predispose to nestling deaths in this hihi population may also affect growth rates.

Nestlings are thought to be more likely to succumb to hyper- than hypothermia (Mertens, 1977) and Low and Part, 2009 showed the temperature-dependent mortality affecting hihi nestlings on Tiritiri Matangi Island was due to high maximum temperatures later in the breeding season. Mertens, 1977 showed that Great tit (*Parus major*) nestlings were more susceptible to high temperatures that cause an immediate risk of hyperthermia, rather than the more chronic effect of mortality through dehydration. The temperature gradient from the northern tip of the North Island of New Zealand to the southern tip is such that the northern areas are classified as subtropical, while the southern are classified as temperate rain forest and it is possible that hihi were adapted to the particular thermal conditions in the areas where they originated. Originally hihi distribution spanned the entire North Island but today all translocated populations are derived from the remnant population on Hauturu and this population may be adapted to site-specific thermal conditions. The hihi population at KS is founded on birds translocated from Tiritiri Matangi Island and the results from these sites suggest that minimum and maximum temperatures outside the 12-30°C range impacts on young nestlings. Thermal tolerance may therefore be an important factor limiting nestling survival in translocated hihi populations.

The association between mortality in young nestlings, hypothermia and starvation seen in the present study can be easily understood because greater energy will be required and utilised in thermoregulation in poorly feathered young chicks of low body mass. Also observed however, was an association between low environmental temperatures and respiratory problems in affected chicks which manifested histopathologically as poor aeration of the lungs and collapse or accumulation of fluid and fibrin in pulmonary airways. Because the lungs of birds are tubular and more rigid than those of mammals, neonatal respiratory distress syndrome due to lack of surfactant is not recognised as a major cause of neonatal death as it is in humans and other mammals. Never-the-less, surfactant secreted from epithelial cells located in atrial walls, air sacs and parabronchi of birds needs to spread into air capillaries in order to maintain expansion and air flow (Bernhard et al., 2001). The slowing of respiration during hypothermia could therefore be a factor which inhibits the spread of surfactant in nestling lungs resulting in the poor aeration and fluid accumulation observed in the present study.

Aspergillosis is known to cause deaths in adult hihi at all current locations although the impact of this disease on each of the translocated populations has not been

quantified. Disease manifests as low-grade chronic respiratory infections through to a severe, acute cause of mortality that may be related to stress and other causes of immunosuppression (Alley et al., 1999). A detailed study of aspergillosis in the Mokoia Island hihi population showed that high mortality in adult birds (Alley et al., 1999) was limiting the population to the extent that all surviving hihi were removed in 2002 (Armstrong et al., 2007). Environmental spore counts revealed very high levels of *Aspergillus fumigatus* spores present on the island, and that spore counts were even higher at the two mainland sites that were also surveyed (Perrott, 2001). The lowest spore counts were found on Hauturu, the island home of the remnant hihi population, while counts from Tiritiri Matangi Island were higher but considerably less than the Mokoia counts (Perrott, 2001). It is thought that the increase in spore levels is a result of environmental disturbance caused by forest clearing since European colonisation of New Zealand. The more highly modified the habitat the higher the spore counts, and urban areas yield the highest counts (Perrott, 2001). KS is on a mainland site in the midst of suburban Wellington and therefore it is likely that the *Aspergillus fumigatus* spore count will also be high. Because the site is highly utilised as a tourist attraction additional anthropogenic stress factors imposed on wildlife within the sanctuary may further predispose to this disease. Foraging adult hihi have been affected by aspergillosis at other sites and it may be unusual to see this disease manifest in nestlings. Since a single nestling only was seen to be affected, the spore count at KS and the incubation period required for disease manifestation need to be established to determine whether aspergillosis is likely to impact significantly on nestling survival in the future.

## **Parasites**

*Plasmodium* infections have recently been implicated in mortalities affecting endemic species populations of conservation value, such as captive mohua/yellowhead (*Mohoua ochrocephala*) (Alley et al., 2008, Derraik et al., 2008) and free-living South Island saddlebacks (*Philesturnus carunculatus carunculatus*) (Hale, 2008). Avian malaria in New Zealand has been detected in a range of native species, including many passerines, and recent research is finding that an increasing number of *Plasmodium spp* are present in native and introduced avian species, some of which may be endemic to the native birds (Castro et al., unpub; Tompkins et al., unpub). There are concerns that avian malaria may qualify as an emerging disease in this country (Derraik et al., 2008).

Detection of haemoparasites may be made indirectly by using serological tests to detect antibodies or directly by microscopic examination of blood smears or impression smears from tissues, and increasingly by using PCR techniques (Jarvi et

al., 2002). Avian species are host to three genera of haemoparasite, *Plasmodium*, *Haemoproteus* and *Leucocytozoon*, that are transmitted by insect vectors and undergo developmental stages in the tissues and the circulating blood cells in the avian host that, after initial acute-phase infection, often progress to chronic or latent lifelong infections (Atkinson and van Riper III, 1991). *Haemoproteus* and *Leucocytozoon* are relatively host-specific, whereas many *Plasmodium spp* occur across a broad range of avian families and it is this characteristic that has facilitated the global spread of avian malaria causing a corresponding wave of extinctions in naive populations (Atkinson and van Riper III, 1991).

Disease-screening of hihi for translocations includes PCR analysis for blood parasites and a haemoparasite, possibly *Plasmodium sp*, has been detected in some blood samples collected from hihi on Tiritiri Matangi Island (Makan, 2009). Identification of the parasite has yet to be confirmed. Histopathological examination showed that a 26 day old nestling at KS died with evidence of a haemoparasite infection, and since the founder stock for this population are derived from Tiritiri Matangi Island it is possible that the parasite was introduced from this source. The identity of the haemoparasite in this single nestling was not determined and further studies may show that the parasite evolved with hihi and is endemic to New Zealand, or alternatively this may be a spill-over from exotic species known to carry malaria, such as blackbirds (*Sternus merula*) and thrushes (*Turdus philomelos*).

Both PCR and microscopic blood film examination failed to detect avian haemoparasites in the nestling from KS. Alley et al, (2008) report similar findings following an outbreak of avian malaria in a small captive population of mohua (*Mohoua ochrocephala*). Blood film examination and PCR testing of blood and fixed tissues from mohua showed negative results for avian haemoparasites despite the presence of *Plasmodium*-like intracytoplasmic bodies in pulmonary endothelial cells and hepatic and splenic histiocytes. Electron microscopy confirmed the histological findings and identified the causative organism as *Plasmodium sp*. Although PCR tests for malaria show high specificity they have relatively low sensitivity and may not detect 20-40% of low grade infections (Jarvi et al., 2002). Similarly, microscopic examination of blood films for malarial parasites is generally only useful in acute phases of infection when parasites are released into the peripheral circulation in large numbers (Jarvi et al., 2002). In naive populations disease manifestations may not follow the normal infectious process (Pierce, 2000). For example, penguins exposed to avian malaria may die from the effects of *Plasmodium* schizonts in tissue phase only, with no detectable presence in the erythrocytes (Pierce, 2000). If this is also the case with hihi, it may be difficult to detect and monitor the impacts on the populations and further investigations will be necessary to identify the haemoparasites present in

reintroduced hihi populations. This isolated case indicates that further surveillance may be warranted to determine infection status within the population of hihi at KS and that this might be extended to survey other species that are possible carriers of the disease, or that may be susceptible.

Coccidia is a cause of per-acute death in captive juvenile hihi and oocysts were found in free-living hihi from populations at Hauturu (Pauli, 2000), Mokoia (Jan-Feb 1998) and Tiritiri Matangi (Jan, Feb and Aug 1999) islands (Twentyman, 2001). In affected chicks two or more periods of shedding occurred; the first while the chicks were still in the nest with subsequent periods post-fledging (Twentyman, 2001). The earliest recorded period of shedding was in a 9 day old nestling while the source of infection was most likely adult carriers (Twentyman, 2001). There was no evidence of coccidia in nestlings from KS which suggests a low incidence of coccidia at this site. However, hihi translocated to KS receive prophylactic treatment for coccidia, intestinal worms and aspergillosis at capture (Makan, 2009), and therefore levels of coccidia in the population may have been suppressed. Further screening would be required to determine whether coccidia levels in the population increase over time.

Nest ectoparasites mostly affect the growth and survival of nestlings, although some such as *Ornithonyssus bursa* (tropical fowl mite) that require a blood meal every 4-6 weeks, live more-or-less permanently on the avian host and have the potential to affect all life stages (Powlesland, 1978). Mites are introduced to nests by adult birds and when not feeding burrow deep into the nest substrate (Powlesland, 1978). In a study of starlings in nest boxes, Powlesland, 1978 found that once chicks fledged the nest mites move to the top of the nest box in order to recolonise fledglings or adults to ensure mite survival through to the next breeding season (Powlesland, 1978). Mite infestations vary within the population; nests are seldom colonised by mites prior to eggs hatching and some nests may remain free of mites, while others become heavily infested (Powlesland, 1978). The predominant ectoparasites *Ornithonyssus bursa* (nest mites) and *Hemialges spp* (feather mites) found in the nests at KS were consistent with the findings from hihi nests at other sites (Higgins et al., 2001) such as Mokoia Island and Tiritiri Matangi Island. Nest mite numbers at Mokoia Island and Tiritiri Matangi Island have been actively managed to reduce nestling mortality caused by these parasites (Armstrong et al., 2002). In contrast to KS, nests and nestlings on Mokoia Island and Tiritiri Matangi Island were visibly infested and nestlings have been known to leave the nest box prior to fledging to escape from biting nest mites (Armstrong et al., 2002). High mite burdens have the potential to reduce the haemoglobin and PCV in affected species. However, frequent handling of the nestlings and frequent nest checks performed throughout the course of this study detected few mites in the nests and therefore there was no evidence that mite burdens

at KS impacted on the PCV results obtained. The relatively low numbers of nest mites at KS compared to other sites may be attributed to the lower ambient temperatures that slow the population growth rates of ectoparasites (A. Heath, pers. comm.).

### **Health parameters in live nestlings**

A simple test that provides a reliable and reproducible indicator of the red cell component of the blood (Samour, 2006) and that has been used as an indicator of fitness (Cuervo et al., 2007, Morrison et al., 2009) is the microhaematocrit (Hct) or packed cell volume. The % PCV gives an indication of the oxygen carrying capacity of the blood as a percentage of total blood volume, and declines may be due to disease, parasite burden and malnutrition (Cuervo et al., 2007). Hct (L/L) is a calculated result derived from red cell indices that are measured in an automated haematological analyser or calculated from the PCV result. As previously discussed, there was no evidence that PCV was affected by nest mites at KS. The evidence linking PCV values and body condition or fitness in birds is contradictory. Partial cross-fostering studies indicate that although the relationship is weak, PCV is related to body condition in barn swallow nestlings (*Hirundo rustica*) (Cuervo et al., 2007) but it is not related to body condition in tree swallow nestlings (Morrison et al., 2009). There was no correlation between nestling weight and PCV at KS, suggesting that it is possible that for hihi PCV is not correlated to body condition.

Normal PCV values for many pet bird species are >39%, according to data collected by the California Avian Laboratory in the USA (mainly derived from parrots), and limited data from nestling birds suggests that lower values may be expected in nestlings up to 3-6 months of age (Fudge, 2000). However paediatric guidelines for avian species are lacking (Fudge, 2000) and there is very little haematological data pertaining to hihi. Where species specific information is not available conclusions are limited because comparisons of data across species may not be relevant. Age-related PCV results were determined for 16 clinically normal kori bustard (*Ardeotis kori*) chicks by sampling the chicks at monthly intervals (Samour, 2006). The mean value for initial samples taken at 1 month of age was 23 ( $\pm 7$ )% rising to plateau at 39.9 ( $\pm 9$ )% at 5 months of age before increasing to 47 ( $\pm 9$ )% at 12-15 months of age (Samour, 2006). The PCV results for the 23 blood samples collected from hihi nestlings aged 18-26 days ranged from 23-39%, with mean PCV of 31 ( $\pm 2$ ) % and these results are consistent with those of Samour, 2006. The nestlings sampled were in a narrow age range (18-26 days) and the results showed no correlation between nestling age and PCV.

Partial cross-fostering studies of barn swallow (Cuervo et al., 2007) and tree swallow (Morrison et al., 2009) nestlings showed that the nest in which the chicks were raised influenced the PCV result but that the nest of origin did not. This indicates that PCV in these birds is not heritable and suggests that parental care and environmental conditions have a significant effect on PCV values (Cuervo et al., 2007, Morrison et al., 2009). Correlation was also found for PCV between siblings at a given nest box, suggesting that nest specific conditions impact on the PCV values for hihi nestlings. A number of factors that could influence PCV on a nest-by-nest basis include provisioning by the parent birds; the presence of ectoparasites, coccidia or haemoparasite infection; microclimate conditions at the nest; and the number of nestlings present. It was found that PCV values for nestlings from the third clutch were lower than the PCV values obtained for second clutch nestlings and this suggests the fitness and provisioning capabilities of the parent bird(s) may be important factors.

## **Conclusions**

This study has identified a number of factors that impact adversely on the nestling population at KS. The implications of ventriculitis, caused by insect remnant penetration of the gastrointestinal tract (Rippon et al., Chapter 3 submitted), and the presence of *Candida albicans* as a colonising organism that has the potential to cause disease in nestlings (Rippon et al., Chapter 4 submitted), have been discussed in separate papers. However, the major influence on nestling survival over the study period appears to be temperature and it is likely that thermoregulation in nestlings is not sufficiently developed to compensate for temperature drops below 11°C. This may be alleviated where the habitat is mature enough to provide natural nesting cavities, as it is likely that the nest boxes provided for breeding purposes lack the same degree of insulation. Further work would be necessary to confirm these findings, and the use of temperature data-loggers to measure the temperature within the nest box microclimate might be one way to achieve this. Low temperatures may also affect numbers of insect prey, thereby reducing the available food supply. In the short term, it may be possible to develop management strategies to counteract the effects of low temperatures; extra provisioning during inclement weather may reduce the amount of time parent birds spend away from the nest; weather protection or insulation might be incorporated into the nest box design.

Although infectious pathogens were present in the nestling population, they appeared to have minimal impact on survival, causing mortality in relatively small percentages of the population during the study period. This may be somewhat misleading as fledgling survival and recruitment into the population was unknown at the time of

writing. However, there is always potential for infectious disease processes to increase in prevalence and virulence, and since this population is still in the establishment phase, ongoing surveillance is important to detect such changes before major mortality events occur.

## **ACKNOWLEDGEMENTS**

Thanks to Raewyn Empson, Matu Booth, the staff and volunteers of Zealandia – Karori Sanctuary for collecting and submitting samples and data used in this study. Many thanks for the invaluable advice and technical expertise of Allen Heath and staff at AgResearch Ltd, Wallaceville for identifying and quantifying the ectoparasites from nesting material. Thanks to Jane Kerridge of Medlab Wanganui who provided the facilities for much of the laboratory work and to Doug Hopcroft and staff at Manawatu Microscopy and Imaging Centre. We acknowledge the outstanding technical help from IVAB's staff including Elaine Booker, Evelyn Lupton and Nicola Wallace, and the members of the Ecology Group including Cleland Wallace, Tracy Harris, Sharon Tozer and Paul Barrett who were always willing to help. Thanks to Alasdair Noble for statistical advice. Particular mention is worthy of the tireless efforts and input from Ellen Schöner, and for assistance in the field from Monica Awasthy. Scholarship grants from the New Zealand Wildlife Health Centre Trust Research Fund, Graduate Women Manawatu Charitable Trust and J.P. Skipworth (Ecology) Fund were used to fund some of the work undertaken.



## REFERENCES

- ALLEY, M. R., CASTRO, I. & HUNTER, J. E. B. (1999) Aspergillosis in hihi (*Notiomystis cincta*) on Mokoia Island. *New Zealand Veterinary Journal*, 47, 88-91.
- ALLEY, M. R., FAIRLEY, R., MARTIN, D., HOWE, L. & ATKINSON, T. (2008) An outbreak of avian malaria in captive yellowheads/mohua (*Mohoua ochrocephala*). *New Zealand Veterinary Journal*, 56 (5), 247-51.
- ANGEHR, G. R. (1984) Ecology and behaviour of the stitchbird with recommendations for management and future research. *Internal Report to the New Zealand Wildlife Services*. Wellington, New Zealand, Department of Internal Affairs.
- ARMSTRONG, D. P., CASTRO, I. & GRIFFITHS, R. (2007) Using adaptive management to determine requirements of re-introduced populations: The case of the New Zealand hihi. *Journal of Applied Ecology*, 44, 953-62.
- ARMSTRONG, D. P., DAVIDSON, R. S., DIMOND, W. J., PERROTT, J. K., CASTRO, I., EWEN, J. G., GRIFFITHS, R. & TAYLOR, J. (2002) Population dynamics of reintroduced forest birds on New Zealand islands. *Journal of Biogeography*, 29, 609-621.
- ATKINSON, C. T. & VAN RIPER III, C. (1991) Pathogenicity and epizootiology of avian haematozoa: *Plasmodium*, *Leucocytozoon* and *Haemoproteus*. IN LOYE, J. E. & ZUK, M. (Eds.) *Bird-Parasite Interactions*. Oxford, UK, Oxford University Press.
- BERNHARD, W., GEBERT, A., VIETEN, G., RAU, G. A., HOHLFELD, J. M., POSTLE, A. D. & FREIHORST, J. (2001) Pulmonary surfactant in birds: coping with surface tension in a tubular lung. *American Journal of Physiology - Regulatory, Integrative and Comparative Physiology*, 281, 327-37.
- CASTRO, I., BRUNTON, D. H., MASON, K. M., EBERT, B. & GRIFFITHS, R. (2003) Life history traits and food supplementation affect productivity in a translocated population of the endangered hihi (stitchbird, *Notiomystis cincta*). *Biological Conservation*, 114, 271-280.
- CASTRO, I., MINOT, E. O., FORDHAM, R. A. & BIRKHEAD, T. R. (1996) Polygyandry, face-to-face copulation and sperm competition in the hihi *Notiomystis cincta* (Aves: Meliphagidae). *Ibis*, 138, 765-71.
- CUERVO, J. J., MOLLER, A. P. & DE LOPE, F. (2007) Haematocrit is weakly related to condition in nestling barn swallows *Hirundo rustica*. *Ibis*, 149, 128-34.
- DAWSON, R. D., LAWRIE, C. C. & O'BRIEN, E. L. (2005) The importance of microclimate variation in determining size, growth and survival of avian offspring: experimental evidence from a cavity nesting passerine. *Oecologia*, 144, 499-507.
- DERRAIK, J. G. B., TOMPKINS, D. M., ALLEY, M. R., HOLDER, P. & ATKINSON, T. (2008) Epidemiology of an avian malaria outbreak in a native bird species (*Mohoua ochrocephala*) in New Zealand. *Journal of the Royal Society of New Zealand*, 38, 237-42.
- DRISKELL, A., CHRISTIDIS, L., GILL, B. J., BOLES, W. E., BARKER, F. K. & LONGMORE, N. W. (2007) A new endemic family of New Zealand passerine

birds: Adding heat to a biodiversity hotspot. *Australian Journal of Zoology*, 55, 73-78.

- EMPSON, R. & BOOTH, M. (2009) Zealandia - Karori Sanctuary Report to Hihi Recovery Group Meeting April 2009. Unpub. <http://www.hihiconservation.com> (accessed 16/11/2009).
- EMPSON, R., GOUDSWAARD, R. & BOOTH, M. (2008) Report on hihi survival and productivity at Karori Sanctuary, 2008. Unpub. <http://www.hihiconservation.com> (accessed 16/11/2009).
- EWEN, J. G., FLUX, I. & ERICSON, P. G. P. (2006) Systematic affinities of two enigmatic New Zealand passerines of high conservation priority, the hihi or stitchbird *Notiomystis cincta* and the kokako *Callaeas cinerea*. *Molecular Phylogenetics and Evolution*, 40, 281-284.
- EWEN, J. G., THOROGOOD, R., NICOL, C., ARMSTRONG, D. P. & ALLEY, M. (2007) *Salmonella* Typhimurium in Hihi, New Zealand. *Emerging Infectious Diseases*, 13, 788.
- FRIEND, M. & FRANSON, J. C. (Eds.) (1999) *Field Manual of Wildlife Diseases: General Field Procedures and Diseases of Birds*, Washington DC, USA, U.S. Geological Survey.
- FUDGE, A. M. (Ed.) (2000) *Laboratory Medicine: Avian and Exotic Pets*, Philadelphia, USA, W. B. Saunders Company.
- HALE, K. A. (2008) Disease outbreak amongst South Island saddlebacks (*Philesturnus carunculatus carunculatus*) on Long Island. *Research and Development Series 289*. Wellington, New Zealand, Department of Conservation.
- HAZEN, K. C. & HOWELL, S. A. (2003) *Candida*, *Cryptococcus* and other yeasts of medical importance. IN MURRAY, P. R., BARON, E. J., JORGENSEN, J. H., PFALLER, M. A. & YOLKEN, R. H. (Eds.) *Manual of Clinical Microbiology*. 8 ed. Washington DC, American Society for Microbiology Press.
- HELLGREN, O. & WALDENSTROM, J. (2004) A new PCR assay for simultaneous studies of *Leucocytozoon*, *Plasmodium* and *Haemoproteus* from avian blood. *Journal of Parasitology*, 90, 797-802.
- HENDRIX, C. (1997) Chapter 6 Internal Parasites. IN PRATT, P. (Ed.) *Laboratory Procedures for Veterinary Technicians*. St Louis, Missouri, Mosby Year Book.
- HIGGINS, P. J., PETER, J. M. & STEELE, W. K. (2001) Stitchbird. IN HIGGINS, P. J., PETER, J. M. & STEELE, W. K. (Eds.) *Handbook of Australian, New Zealand and Antarctic Birds. Volume 5: Tyrant-flycatchers to Chats*. Melbourne, Australia, Oxford University Press.
- JARVI, S. I., SCHULTZ, J. J. & ATKINSON, C. T. (2002) PCR diagnostics underestimate the prevalence of avian malaria (*Plasmodium relictum*) in experimentally-infected passerines. *Journal of Parasitology*, 88, 153-8.
- LOW, M. (2006a) The energetic cost of mate guarding is correlated with territorial intrusions in the New Zealand stitchbird. *Behavioural Ecology*, 17, 270-76.
- LYNCH, J. (1995) Back to the future: Karori from reservoir to wildlife sanctuary. *Forest and Bird*, 275, 12-19.

- MAKAN, T. (2009) A critique of disease-screening requirements for community-managed species translocations: A case study of hihi (*Notiomystis cincta*). *Unpublished Ark in the Park Technical Report*. Auckland, New Zealand, Waitakere Branch Royal Forest and Bird Society of New Zealand Inc.
- MERTENS, J. A. L. (1977) Thermal conditions for successful breeding in great tits (*Parus major* L.) I. Relation of growth and development of temperature regulation in nestling great tits. *Oecologia*, 28, 1-29.
- MORRISON, E. S., ARDIA, D. R. & CLOTFELTER, E. D. (2009) Cross-fostering reveals sources of variation in innate immunity and haematocrit in nestling tree swallows *Tachycineta bicolor*. *Journal of Avian Biology*, 40, 573-8.
- OLIVER, W. R. B. (1955) *New Zealand Birds*, Wellington, New Zealand, A.H. & A.W. Reed.
- PAULI, J. M. (2000) Diseases of NZ native birds: Disease encountered in captive breeding of the stitchbird and shore plover at the National Wildlife Centre Mt Bruce. *Wildlife Health in Conservation*. Massey University, Palmerston North, Veterinary Continuing Education.
- PEREYRA, M. E. & MORTON, M. L. (2001) Nestling growth and thermoregulatory development in subalpine dusky flycatchers. *The Auk*, 118, 116-136.
- PERROTT, J. K. (2001) The ecology of *Aspergillus fumigatus* and implications for wildlife conservation in modified environments. *Wildlife Ecology*. Palmerston North, Massey University.
- PIERCE, M. A. (2000) Hematozoa. IN SAMOUR, J. (Ed.) *Avian Medicine*. London, UK, Mosby Publishers.
- POWLESLAND, R. G. (1976) A study of the relationship between the starling *Sturnus vulgaris* and the haematophagous mite *Ornithonyssus bursa*. *Zoology*. Palmerston North, New Zealand, Massey University.
- POWLESLAND, R. G. (1978) Behaviour of the haematophagous mite *Ornithonyssus bursa* in starling nest boxes in New Zealand. *New Zealand Journal of Zoology*, 5, 395-9.
- QUINN, P. J., CARTER, M. E., MARKEY, B. K. & R, C. G. (1994) *Clinical Veterinary Microbiology*, London, UK, Wolfe Publishing.
- SAMOUR, J. (2006) Diagnostic value of haematology. IN HARRISON, G. J. & LIGHTFOOT, T. L. (Eds.) *Clinical Avian Medicine*. Palm Beach, Florida, USA, Spix Publishing.
- TAYLOR, S. & CASTRO, I. (2000) Hihi standard operating procedures. Wellington, New Zealand, Unpublished report, Department of Conservation.
- TAYLOR, S., CASTRO, I. & GRIFFITHS, R. (2005) Hihi/Stitchbird (*Notiomystis cincta*) Recovery Plan 2004-2009. *Threatened Species Recovery Plan 54*. Wellington, New Zealand, Department of Conservation.
- TWENTYMAN, C. M. (2001) A study of coccidial parasites in the hihi (*Notiomystis cincta*). *Veterinary Science*. Palmerston North, Massey University.
- TWORT, F. W. (1924) An improved neutral red, light green double stain for staining animals, parasites, micro-organisms and tissues. *Journal of State Medicine*, 32, 351.

YOUNG, B. J. (1969) Staining of fungal hyphae in tissue sections. *Journal of Medical Laboratory Technology*, 25, 342-6.

### **3 Traumatic ventriculitis following consumption of introduced insect prey (Order Hymenoptera) in hihi/stitchbird (*Notiomystis cincta*) nestlings**

---

**ABSTRACT:** Nestling mortality in the endangered and endemic hihi/stitchbird (*Notiomystis cincta*) was studied over the 2008-09 breeding season at Zealandia – Karori Sanctuary, Wellington, New Zealand. Twenty-five dead nestlings were necropsied and traumatic ventriculitis, a rare disease syndrome in passerines, was found in seven (28%). Histopathology showed single or multiple granulomas centered on chitinous insect remnants lodged within the gizzard mucosa, muscle layers and ventricular or intestinal serosa. The insect remnants were confirmed as bee or wasp stings (Hymenoptera) using light and electron microscopy. Bacteria and/or yeasts were also found in some granulomas, and death was due to bacterial septicaemia in four cases. Endemic New Zealand birds are likely to lack evolutionary adaptations required to safely consume introduced honey bees (*Apis mellifera*) and vespulid wasps (*Vespula germanica*, *V. vulgaris*). However, these insects are attracted to feeding stations used to support translocated hihi populations. As contact between bees, wasps and the endemic fauna of New Zealand seems inevitable, it may be necessary to minimise the numbers of these introduced insects in areas set aside for ecological restoration.

*Key words:* traumatic ventriculitis, hihi, stitchbird, *Notiomystis cincta*, honey bee, vespulid wasp, Hymenoptera, sting apparatus.

#### **INTRODUCTION**

Traumatic ventriculitis is rare in free-living birds (Gupta and Trapp 1971), and presents a novel disease syndrome affecting a population of endangered New Zealand passerines. The hihi/stitchbird (*Notiomystis cincta*) is a small, sexually dimorphic passerine endemic to New Zealand (Higgins et al. 2001). Originally found throughout the North Island and on some adjacent offshore islands, hihi became confined to a single wild population on Hauturu (Little Barrier Island) (Oliver 1955) from which they have been translocated to two offshore islands and three mainland sites. The interacting ecological factors that limit the long term survival of the different populations may vary (Armstrong et al. 2002). To compensate for the lack of natural cavities in restored forest habitat, nest boxes have been provided at translocation sites (Armstrong et al. 2007) and it has been necessary to control nest mite (*Ornithonyssus sp*) numbers because mite infestations can cause nestling deaths (Armstrong et al. 2002). Aspergillosis (Alley et al. 1999) has been suggested as a

limiting factor for the establishment of the Mokoia Island population (Perrott 2001, Armstrong et al. 2007) and Low (2009) suggested that predation by the ruru or native owl (*Ninox novaeseelandiae*) may also cause mortality during the breeding season (Low and Part 2009). However, food availability is the only factor which has been found experimentally to affect population growth (Castro et al. 2003, Armstrong et al. 2007).

Hihi are omnivorous and forage for invertebrates, nectar and fruits to provide important nutrients in their natural diet (Craig et al. 1981, Rasch 1985, Castro and Robertson 1997, Perrott and Armstrong 2000), while seasonal variations in foraging behavior reflect food availability throughout the year (Angehr 1984, Lovegrove 1985, Castro 1995, Perrott 1997). Hihi nestlings are almost exclusively fed invertebrates provided by the parent birds for the first 8-10 days of life (Higgins et al. 2001). When provisioning chicks, some avian insectivores are known to avoid small insects in favor of larger prey to maximize their foraging effort (Krebs and Avery 1985, Kaspari and Joern 1993, Saffer and Calver 1997). Management strategies for all translocated hihi populations include ongoing population monitoring and provision of supplementary food, most often sugar-water (Castro et al. 2003, Taylor et al. 2005). Hihi provisioned with carbohydrate food on Mokoia Island did not reduce the overall amount of time spent foraging, but changed their foraging behavior to allocate most of their effort towards invertebrate feeding (Armstrong et al. 1999, Armstrong and Perrott 2000).

Social bees and wasps of the Order Hymenoptera are highly successful invaders that rely on their sting, venom and numbers to defend colonies and territories (Beggs 2000), whereas New Zealand's endemic bees and wasps are from primitive lineages and the majority lack stings (Miller 1974, Donovan 1980). With abundant food and very few predators or competitors, social bees and wasps have readily established throughout New Zealand (Beggs 2000). Honey bees (*Apis mellifera*) rely totally on nectar and pollen and were introduced primarily to ensure pollination of introduced plants as well as for honey-production (Donovan 1980). Self-introduced German (*Vespula germanica*) and common (*V. vulgaris*) wasps have established across a wide range of habitats and altitudes (Beggs 2000) in urban and rural landscapes (Harris et al. 1991). Formidable competitors across much of the forest habitat (Harris et al. 1991), both species of wasps compete with native and endemic avian species for nectar and insects (Thomas et al. 1990, Beggs and Rees 1999) and there is growing concern about the role of these species as conservation pests (Beggs 2000). Honey bees (Somerville 2000) and vespulid wasps (Spurr 1996) are attracted to alternative carbohydrate sources such as the sugar-water feeders provided for translocated hihi populations.

This study investigated the causes of mortality in hihi nestlings during the 2008-09 breeding season. It was undertaken in a mainland population of hihi that were translocated to Zealandia – Karori Sanctuary from Tiritiri Matangi Island in 2005-06.

## **MATERIALS AND METHODS**

### **Study population**

Zealandia - Karori Sanctuary (41°17'S, 174°44'E) is a mainland island sanctuary situated in suburban Wellington, on the south coast of New Zealand's North Island. The 225-ha reserve has been subject to an intensive revegetation program, and is surrounded by a mammalian predator proof fence. Ecological restoration has increased the available habitat for native species, while translocations of rare or threatened endemic fauna have further increased biodiversity. From February to May 2005, reintroduction of hihi began with the release of 60 (55 juvenile and 5 adult) birds sourced from Tiritiri Matangi Island (Empson et al. 2008). A similar cohort was released in 2006, while additional smaller hihi introductions over subsequent years have contributed to the population (Empson et al. 2008). Management of this population includes color banding all individuals for monitoring survival and breeding success, as well as provision of nest boxes and supplementary food (sugar-water, Wombaroo™ Insectivore mix) (Empson and Booth 2009). The female parent is solely responsible for nest building and incubating, and once she has selected the area she will nest in, generally remains site specific throughout the season (Castro 1995). The male parent may assist in provisioning the young (Castro et al. 2003). Hihi may rear up to three clutches per season and the altricial nestlings remain in the nest for 28-30 days (Higgins et al. 2001).

### **Monitoring and sampling**

At Zealandia – Karori Sanctuary over the 2008-09 hihi breeding season, all hihi used the nest boxes provided for breeding purposes allowing ready access to the nest contents. Karori staff and volunteers closely monitored the general activities of hihi throughout the breeding season. Data from feeder stations and nest boxes were collected and maintained as the progress for each clutch was recorded from nest building, through egg laying, to fledging. Nest boxes were checked every 2-3 days, and daily during periods of change such as when eggs were due to hatch, or nestlings due to fledge. Further checks were made when sampling was scheduled. Infertile and abandoned eggs and dead chicks were removed from the nests, encouraging females to nest again. Dead birds for necropsy examination were recovered and submitted to the New Zealand Wildlife Health Centre (NZWHC) at Massey University, Palmerston

North. At Karori, staff collected gastrointestinal (oral and cloacal) swabs for microbiology before preserving the carcass for histopathology. Sample collection from nestlings at Zealandia – Karori Sanctuary was approved by the Massey University Animal Ethics Committee, Palmerston North (08/96) and the Department of Conservation, Wellington Conservancy (Low Impact Research Permit Number WE/346/RES).

## **Histopathology**

For each of the dead nestlings, cause of death was diagnosed by necropsy examination and histopathology. Dead featherless nestlings were fixed whole in 10% buffered formalin and feathered chicks were incised down the ventral midline so that the visceral organs were exposed before fixation. Tissue blocks from neonates and very small nestlings were cut in transverse sections along the length of the body, so that the whole bird was processed. For larger birds, four to five cross-sections were obtained along the length of the body. Sections were routinely processed and embedded in paraffin blocks from which 5µm sections were cut and stained using haematoxylin and eosin (H&E) staining techniques. Following microscopic examination, further sections were cut to access tissues or lesions deeper in the blocks, or to confirm the presence of bacteria or fungi using Gram-Twort (Twort 1924) or Young's fungal (Young 1969) stains.

Honey bees (*Apis mellifera*), collected and euthanased by a local apiarist, were fixed whole in 10% buffered formalin. The posterior abdomen from each bee was processed and embedded in paraffin. Serial sections were cut and stained using H&E staining techniques. Dissected stings from bees and wasps (donated from the archived collection held by the Ecology Laboratory, Massey University, Palmerston North) were fixed, processed, sectioned and stained in the same manner.

## **Microbiology**

Gastrointestinal (oral and faecal or cloacal) swabs collected into Amies transport medium from live and dead hihi were examined using routine methods for bacterial and fungal isolation (Quinn et al. 1994). Columbia 5% Sheep Blood agar (CBA) (Fort Richard Laboratories, New Zealand) was inoculated and incubated aerobically at 35°C for 3 days, and Sabouraud's Dextrose agar (SDA) with antibiotics (Fort Richard Laboratories, New Zealand) was inoculated and incubated aerobically at 25°C for 10 days. Pure subcultures on SDA and CBA were made for identification by colonial characteristics and Gram stain morphology. Diagnostic tests including germ tube production (Quinn et al. 1994) and specific growth characteristics on CHROMagar™



*Candida* agar (Fort Richard Laboratories, New Zealand) (Hazen and Howell 2003) were undertaken where necessary.

### **Electron Microscopy**

Sample preparation and electron microscopy of bee and wasp samples was undertaken by the staff at the Manawatu Microscopy and Imaging Centre (MMIC), Massey University, Palmerston North, New Zealand.

Sting apparatus dissected from honey bees was processed and sectioned for transmission electron microscopy (TEM). The sting samples required extended fixation, dehydration and resin infiltration because of the density of the hard chitinous material. The samples were vacuum infiltrated in primary fixative (3% glutaraldehyde, 2% formaldehyde in 1M phosphate buffer, pH 7.2) and fixed for 4 hours at room temperature (RT), followed by 3 buffer washes at RT. Secondary fixation, 1% OsO<sub>4</sub> in the same buffer for 1 hour was followed by 3 more buffer washes then dehydration through a graded acetone series (25%, 50%, 75%, 95%, 2x 100%). Overnight infiltration on a stirrer of a 50:50 resin acetone mix (Procure 812 resin) was followed by 2x changes of 100% resin on a stirrer (overnight and for 8 hours). Samples were embedded in fresh resin in silicone rubber moulds that were cured at 60°C for 48hrs. Blocks were trimmed then sectioned at 100nm using diamond knife and ultra-microtome, the sections 'stretched'<sup>™</sup> using chloroform vapor ('waved'<sup>™</sup> over the sections on an old grid), then picked up on a copper grid using Sellotape-chloroform cement to 'stick'<sup>™</sup> the sections to the grid. The grid-mounted sections were double stained with saturated uranyl acetate in 50% ethanol (4 min) followed by lead citrate (4 min). Sections were viewed and analysed in a Philips CM10 Transmission Electron Microscope with SIS Morada high resolution digital camera system.

Scanning electron microscopy (SEM) was used to compare the sting apparatus of honey bees (*Apis mellifera*) and the two species of vespulid wasp (*V. vulgaris* and *V. germanica*) present in the local area. Insect legs were included for comparison. Sting apparatus and legs dissected from honey bees and vespulid wasps were prepared for SEM. Air dried specimens were mounted on aluminum SEM stubs on double sided tape. The stub mounted samples were sputter coated with gold. Samples were viewed in a FEI Quanta 200 Scanning Electron Microscope with digital image capture.

## RESULTS

### Nestling Mortality

During the 2008-09 breeding season, 82 of 146 eggs hatched and from these 50 chicks fledged. Only 19% of first clutch eggs survived to fledging as a result of high hatching failure rate and nestling mortality (Empson and Booth 2009). Including all nesting attempts, 34% of eggs survived to fledging in 2008-09, which was considerably lower than the 46-58% recorded in previous years (Empson and Booth 2009). A total of 32 hihi nestlings died and 25 (78%) were recovered for necropsy examination; fourteen nestlings from the first clutch, nine from the second and two from the third. The 22% of nestlings not recovered have been excluded from the data presented in this paper because the cause of death was unknown.

Ventriculitis lesions were seen in eight (32%) of the nestlings examined, and in seven (28%) of these traumatic ventriculitis was associated with insect remnant penetration. At the time of death, the nestlings were aged 6-19 days. Ventriculitis affected nestlings at unrelated nests throughout the breeding season; two siblings from each first and third clutch nest and four siblings from a second clutch nest. Other causes of mortality were starvation, which caused mortality in 16% of nestlings (age 2-4 days), and poor lung aeration affecting 24% of nestlings (age 3-11 days). First clutch nestlings were most affected (three deaths from starvation and four associated with poor lung aeration), with only a single representative in each category from the second clutch, and none from the third. The remaining deaths (28%) were due to a variety of unrelated causes affecting individual nestlings.

### Pathology

For the eight nestlings with evidence of ventriculitis, disease manifestation was multifactorial and a range of lesions was seen that varied with each case. Pathological changes consistent with traumatic ventriculitis included single or multiple granulomas surrounding insect stings lodged within the gizzard mucosa, muscle layers and ventricular or intestinal serosa (Table 1). These were accompanied by varying degrees of inflammatory response, and associated with bacterial and/or *Candida albicans* infections. Death was found to be due to bacterial septicaemia in four cases.

Both chicks from Nest 1 showed severe mixed heterophilic and lymphoid inflammatory cell infiltrations which extended throughout the gizzard mucosa. A necrotic cellular exudate expanded the inner koilin layer and extended into the epithelial mucosa reaching the base of the mucosa in several places. Within the exudate insect remnants were present and these were often associated with large numbers of yeast-

like organisms typical of *Candida spp* and mixed Gram-positive and –negative bacteria. In one nestling the insect remnants had penetrated through the gizzard mucosa. This remnant measured 100µm in diameter and consisted of three interlocking hollow rods of chitin, typical of a sting cross-section as illustrated in Figs 1 and 2. The pectoral muscle of both nestlings contained numerous small multifocal areas of inflammatory myonecrosis associated with small colonies of Gram-negative bacteria and surrounded by small numbers of heterophils and occasional lymphocytes.

TABLE 1. Lesions associated with ventriculitis in nestlings at Zealandia – Karori Sanctuary.

Nest: Chick ID	Age at		Granuloma	Bacteria	Candida	Myositis Myonecrosis	Diagnoses
	Death (days)	Insect Lesion					
1:A	7	M,VM	++		+++		Ventriculitis - candidiasis
:B	9	K		+++	+++	+++	Ventriculitis - candidiasis
2:A	16	VM,VS	+++	+++		+++	Ventriculitis - bacterial
:B	16	VM,VS	+	+++		+++	Ventriculitis
:C	17	M,VM	++	+++		+++	Acute bacterial myositis Acute bacterial septicaemia
:D	17	M,VM	++	+++		+++	Ventriculitis - focal
3:A	6	M,IS	+++	+++	++	+++	Candida
:B	19	VS,L	+++	+++	++		Peritonitis / hepatitis

+=	mild	K =	koilin	VS =	ventricular serosa
++ =	moderate	M =	mucosa	IS =	intestinal serosa
+++ =	severe	VM =	ventricular muscle	L =	liver

Numerous insect penetration lesions ranging from sting remnants within the mucosa to granulomas within the gizzard muscle layer and on the ventricular serosa were seen in the four chicks from Nest 2. The sting shafts also had cross-sectional morphology typical of Hymenoptera insect stings and barbs were observed on the periphery of some sting remnants in cross-sectional view. The sting remnants were surrounded by variable numbers of inflammatory cells including multinucleate giant cells and some showed early fibrous encapsulation. These nestlings also showed other histological

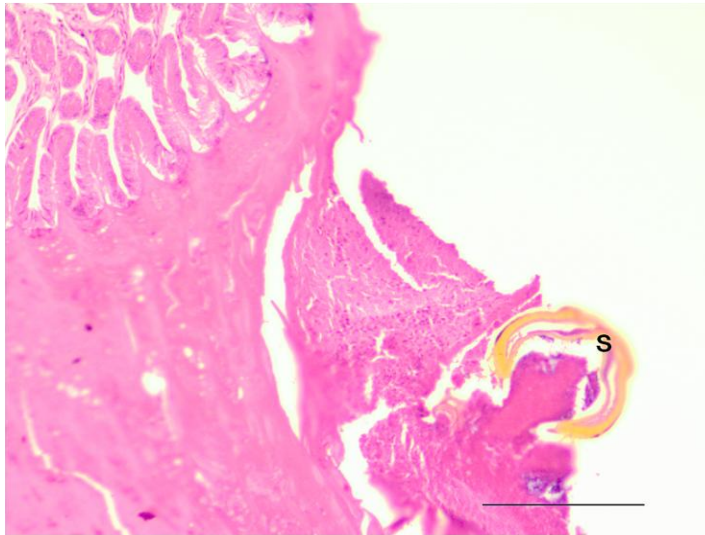


FIGURE 1.

Light photomicrograph of a sting remnant within the ventricular mucosa of a hihi nestling (case 42845) showing inflammatory response adjacent to the remnant. Note how the chitinous remnant is tearing out from the surrounding tissue, an artifact of histological processing. H&E stain. Bar= 150 $\mu$ m.

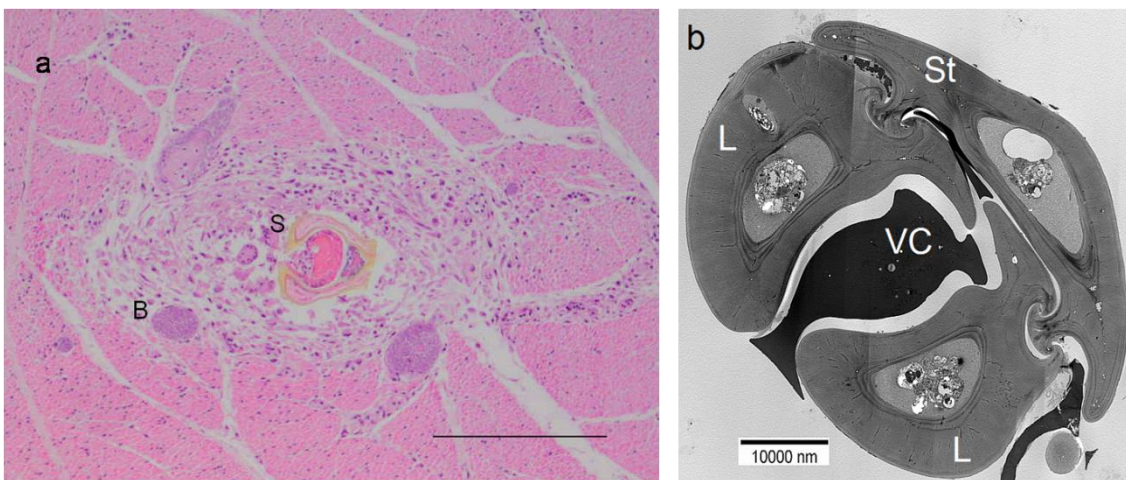


FIGURE 2.

Photomicrographs showing morphological comparison between an insect remnant within a granulomatous lesion and a honey bee sting cross-section.

a. Light photomicrograph showing a sting remnant granuloma within the ventricular muscle wall of a hihi nestling (case 42846). The chitinous sting remnant (S) is surrounded by granulomatous tissue showing discrete bacterial foci (B) of infection. H&E stain. Bar= 150 $\mu$ m.

b. Transmission electron microscope photomicrograph of the distal end of a sting dissected from *Apis mellifera* showing a cross section very close to the tip. Note the rounded oval shape of the sting-tip cross section. The stylet (St) rails may be seen holding the lancets in place. The two hollow lancets (L) are parted at this point allowing venom to escape the venom canal (VC). Uranyl acetate - lead citrate double stain. Bar= 10000nm.

lesions including acute bacterial septicaemia, acute multifocal bacterial myositis, myocarditis (Fig.3), pneumonia, and splenitis.

Chicks from Nest 3 also showed multiple histological lesions associated with traumatic ventriculitis. Koilin shedding caused disruption to half of the gizzard of the first nestling, with *Candida*-like hyphae seen within the hyperplastic, thickened koilin layer. There were multiple insect remnants penetrating to the sub-mucosal level. An insect lesion extending from the serosa into the liver (Fig.4a) caused localized hepatitis in the second chick and this was associated with multiple granulomas situated between the liver and gizzard, a severe localized peritonitis, and bronchopneumonia. *Candida spp* and insect remnants were present in the granulomas.

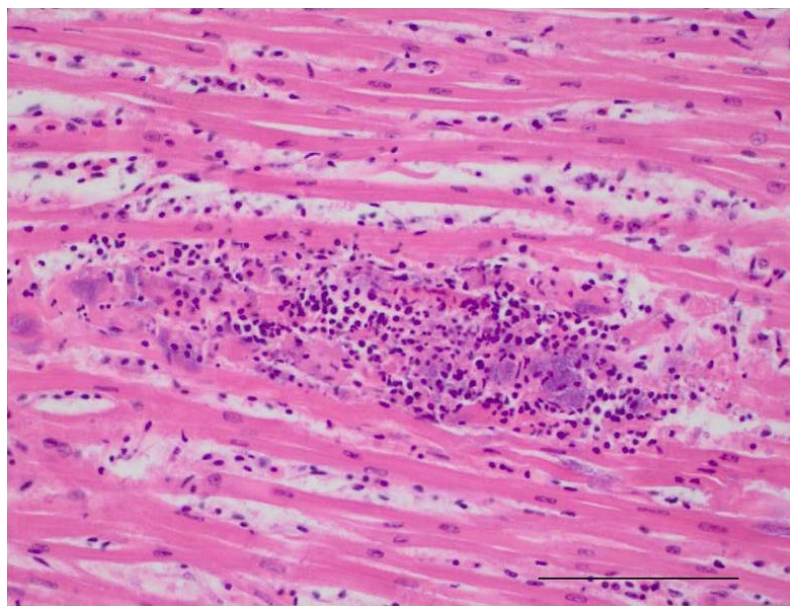


FIGURE 3.

Light photomicrograph showing bacterial infiltration of heart muscle in a hihi nestling (case 42846). Note disruption of the muscle fibers and the bacterial foci within the lesion. H&E stain. Bar=100µm.

### **Microbiology**

Direct smears and aerobic culture from oral and cloacal swabs showed mixed organisms suggestive of normal gastrointestinal flora. Increased numbers (colony forming units) of Gram-negative bacilli (coliforms) were present in post mortem swabs when compared to swabs taken from live nestlings, but there was no noteworthy difference in the bacterial flora recovered from the chicks with ventriculitis. Fungal culture confirmed the presence of *Candida albicans* in the four hihi nestlings with *Candida* lesions, but not in the other nestlings with ventriculitis. Small-moderate creamy-white butyrous colonies with a distinctive 'yeasty' smell became visible on



Sabouraud's Dextrose (SDA) and Columbia Blood (CBA) agar after 24-48 hours incubation. Microscopic examination of Gram stained smears from these colonies revealed Gram-positive (purplish-blue) budding yeast cells (Quinn et al. 1994). A positive germ tube test (Quinn et al. 1994) and characteristic growth on CHROMagar™ Candida medium confirmed the identification of *Candida albicans* (Hazen and Howell 2003).

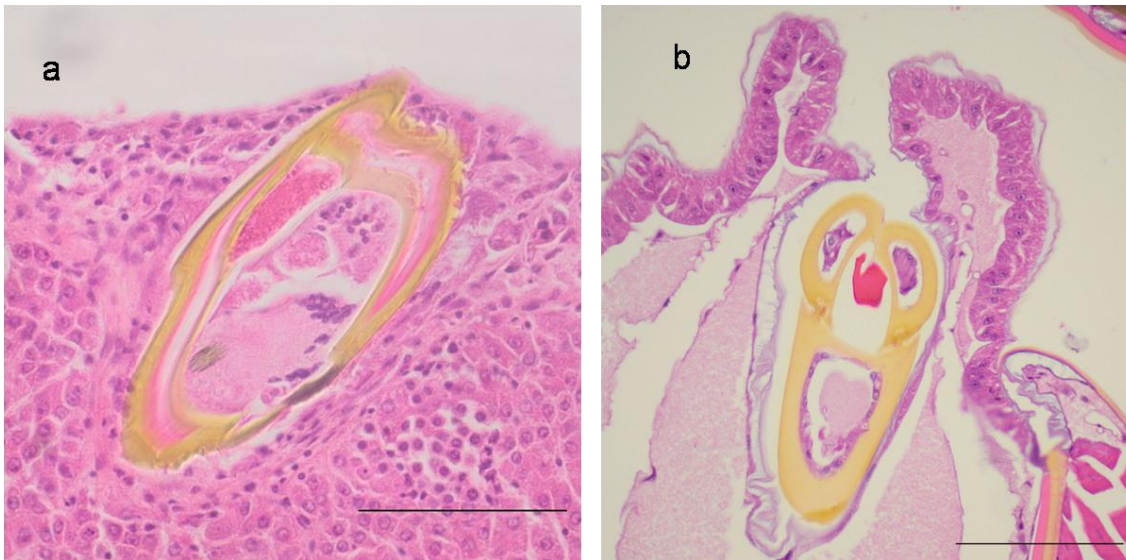


FIGURE 4.

Light microscopy comparison of an insect remnant within a granulomatous lesion in hihi and honey bee sting apparatus.

a. Light photomicrograph of sting remnant located in the liver of a third clutch nestling (case 43078). Note cellular disruption and early inflammatory response in liver cells immediately surrounding the chitinous remnant. H&E stain. Bar=100µm.

b. Light photomicrograph of posterior section of honey bee abdomen showing a slightly oblique cross sectional view of the chitinous sting apparatus. The larger hollow triangular structure is the stylus and the two smaller hollow bean-shaped structures are the lancets. This cross section is distant from the sting tip as the stylus and lancets completely enclose the central venom canal. H&E stain. Bar=100µm.

### Sting Morphology

The insect remnants causing lesions in hihi nestlings all appeared similar in structure, and corresponded to descriptions of the stinging apparatus of the honey bee (*Apis mellifera*) (Dade 1962) or wasp (*Vespula spp*) (Edwards 1980). Considerable technical difficulty was experienced sectioning paraffin embedded insect remnants and stings. The very hard, chitinous rods that make up the sting shaft were prone to tearing from the sections during cutting. This is illustrated in Fig.1 where the gizzard mucosal

tissue has torn away from the sting remnant. Similar difficulties were encountered with attempts to section the posterior abdomen of honey bees, particularly towards the tip of the sting shaft (Fig.4b) and slightly oblique sections usually resulted. However, epoxy resin embedded TEM sections successfully confirmed the cross sectional structure of the sting shaft in a honey bee demonstrating the presence of a stylus, guide rails, lancets and venom canal (Fig.2b). These cross sections strongly resembled the insect remnants found in the hihi granulomas.

The SEM photomicrographs (Fig.5) used to compare the sting apparatus of honey bees and the two species of vespulid wasp present in New Zealand confirmed that sting shaft morphology, comprising a stylet with two barbed lancets, is comparable in all three species. In the honey bee (*Apis mellifera*) and the common wasp (*Vespula vulgaris*) the sting size is very similar (50-65µm diameter), whereas the sting of the German wasp (*V. germanica*) is larger (100-130µm diameter). The difference in size and morphology of a leg and the stinging apparatus of both wasps and bees is shown in Fig.6.

## DISCUSSION

Ventriculitis, affecting the proventriculus, ventriculus (gizzard) and/or the isthmus joining the two organs, varies in aetiology from infectious causes, to traumatic or mechanical damage that may allow secondary infiltration of opportunistic pathogens (Schmidt et al. 2003). Traumatic gastric perforation is known to affect most vertebrate species as an occasional cause of morbidity and mortality when sharp indigestible objects cause penetration of the gastrointestinal tract (Lumeij 1994, Rodriguez-Hermosa et al. 2008). While bones and toothpicks are frequently found in human cases (Rodriguez-Hermosa et al. 2008), hardware such as nails, needles and wire most commonly cause traumatic gastric perforation in domestic or free-living mammals and birds (Awadhiya et al. 1975, Lumeij 1994, Bailey et al. 2001). In birds, mechanical gizzard contractions actively push sharp objects through the muscular wall of the gizzard or proventriculus (Awadhiya et al. 1975, Bailey et al. 2001) and the foraging habits of waterfowl, ratites (Rae 2006) and poultry (galliforms) (Lumeij 1994, Gelis 2006) increase the likelihood of foreign object ingestion, so these species are most commonly affected.

Disease manifestation of traumatic ventriculitis depends on the extent and direction of penetration, but invariably includes a range of sequelae. Complications involve various pathogens and organs and are related to the severity of the lesion, along with

the immune competence and response of the host (Awadhiya et al. 1975, Bailey et al. 2001). A granulomatous inflammatory response may adequately contain the foreign




FIGURE 5. Scanning electron microscope photomicrographs showing similarities in Hymenoptera stings.

- a. *Vespula germanica* - see stylus rails either side of the lancets. Bar=100µm.
- b. *Vespula vulgaris* - see the knife-like barbs of the lancets. Bar=50µm.
- c. *Apis mellifera* - see larger barbs on the lancets. Bar=50µm.



object and/or associated pathogens (Schmidt et al. 2003), but the resulting lesion may itself impair ventricular contractions reducing food digestion and resulting in malnutrition, emaciation or starvation (Lumeij 1994). Migration of the opportunistic microbial pathogens comprising the normal gastrointestinal flora into tissues adjacent to a penetration wound may cause local abscess formation, or as is likely in the present cases, cause acute, generalised infections on entering the blood stream (Lumeij 1994). Disruption of the host immune defense mechanisms also allows yeasts such as *Candida albicans* to infiltrate and proliferate (Schmidt et al. 2003) and juveniles and neonates are considered to be more susceptible since their immature immune system is still developing (Velasco 2000). Other tissues and organs become directly involved if the foreign object continues to penetrate beyond the muscularis (Lumeij 1994). A granulomatous liver lesion with mixed inflammatory cell infiltration that caused severe focal necrotizing hepatitis in a bustard resulted from gastric perforation due to an ingested nail. This was associated with severe chronic ulcerative ventriculitis containing *Candida* hyphae, and a peritoneal abscess due to bacterial infiltration (Bailey et al. 2001). Sporadic cases of traumatic ventriculitis following the ingestion of hardware such as nails and wire have been reported in poultry (Awadhiya et al. 1975, Lumeij 1994) and bustards (Bailey et al. 2001) and ratites (Gupta and Trapp 1971). The lesions and sequelae described in these cases are similar to those seen in the hihi nestlings from Karori.

The sting apparatus of the social bees and wasps is a highly modified ovipositor (Fig.5); the chitinous sting shaft comprises three interlocking hollow rods, the stylet and two lancets, that form a central canal through which venom is pumped (Dade 1962, Edwards 1980). Slender rods with acutely pointed tips, the barbed lancets grip the flesh of the victim to aid penetration and hold the sting *in situ*, while rails on the stylet allow the lancets to move alternately back and forth driving the sting deeper (Fig.7a) and pumping venom into the wound (Dade 1962, Edwards 1980). Because each component of the sting shaft is rigid, indigestible and extremely sharp, and the barbed lancets facilitate unidirectional travel through tissues, stings act much the same as the hardware previously described. Unfortunately this study was not able to determine whether the lesions seen in the hihi were attributable to honey bees or to one of the vespid wasps because it was not possible to visually differentiate the sting remnants using light microscopy.

Although it is possible that some ventriculitis lesions in hihi may have been caused by other hollow chitinous insect remnants such as legs, the size and morphology comparison (Fig.6) indicates that is unlikely. Insect penetration lesions in the crop and intestine of turkeys have been attributed to grasshopper legs (Wickware 1945). When eaten in abundance and as the main food source, grasshoppers cause irritation and

hemorrhagic lesions in turkeys, but not in other birds such as ducks or geese (Wickware 1945). Small insectivores feeding almost exclusively on grasshoppers take the time to remove legs and wings before swallowing the insect (Wickware 1945) and grasshopper sparrows (*Ammodramus savanarrum*) expend considerable energy removing the chitinous exoskeletons before consumption, demonstrating prey recognition that is associated with special behaviors (Kaspari and Joern 1993).

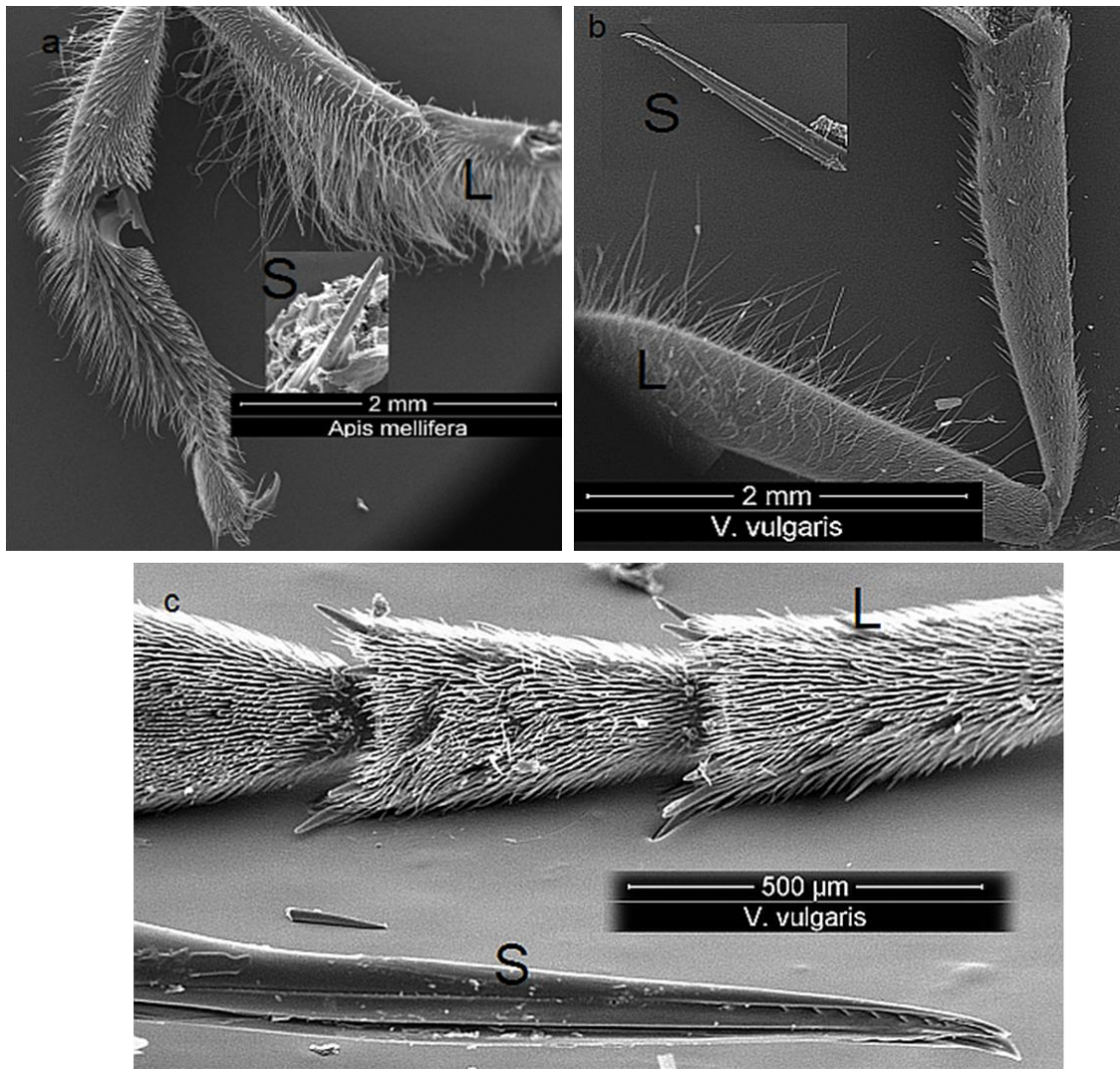


FIGURE 6.

Scanning electron microscope photomicrographs showing size comparison between the sting shafts (S) and legs (L) of Hymenoptera.

a. *Apis mellifera* leg and sting shaft. Bar=2mm.

b. *Vespula vulgaris* leg and sting shaft. Bar=2mm.

c. *Vespula vulgaris* leg (top) and sting shaft. Bar=500μm.

Ingestion of processionary caterpillars has been implicated recently in sporadic epidemics of equine abortions in America (Sebastian et al. 2008) and Australia

(Cawdell-Smith et al. 2009). Penetrating lesions of the gastrointestinal tract of pregnant mares caused by urticating hairs and sharp setae, allow secondary bacterial infiltration to cause inflammation and infection that may result in abortion of the developing fetus (Sebastian et al. 2008). Processionary caterpillars are social species, seasonally found in large numbers, and form 'trains' as they travel to a food source en masse (Diaz 2005, Sebastian et al. 2008). Caterpillars infesting pasture, feed or water that are ingested by mares cause lesions similar to those described in hihi and the other traumatic ventriculitis cases. Accidental consumption, in the case of mares (Sebastian et al. 2008, Cawdell-Smith et al. 2009) or over-consumption in the case of turkeys (Wickware 1945), occurs when seasonal abundance and population explosions of the invertebrate species cause a transient imbalance affecting the food web, and the indigestible and sharp exoskeleton remnants of invertebrates cause traumatic lesions in naive species not adapted to this food source.

Retrospective analyses of cases from the National Wildlife Mortality (NWM) database at Massey University revealed that traumatic ventriculitis caused by chitinous insect remnants is not confined to nestlings. Individual cases reveal hihi deaths due to envenomation, suspected asphyxiation and proposed anaphylactic shock following the ingestion of stinging insects, with insect remnant penetration lesions seen in some of these birds (M.R. Alley, unpub. obs.). Some ingested insects were identified as honey bees (Fig.7b), indicating that individual hihi include honey bees in their own diet as well as feeding these insects to their offspring. There was no pathological evidence that any of the nestlings in this study were the victims of envenomation, suggesting that the bees/wasps were not alive when the parent birds fed them to the offspring. Envenomation has been seen previously in adult and juvenile hihi and results in sudden death due to a toxic cardiomyopathy (Alley 2007).

Where venomous bees and wasps are endemic, avian predators such as bee-eaters and shrikes have evolved a suite of adaptations and behaviors to render these insects safe for consumption (Fry 1968, Saffer and Calver 1997, Tryjanowski et al. 2003). Most demonstrate prey recognition (Fry 1968, Tryjanowski et al. 2003) and specific stereotypic behaviors are used to process venomous prey (Fry 1968). Rainbow bee-eaters (*Merops ornatus*) catch their prey on the wing, returning to a nearby branch with the captured insect, where they proceed to first beat and then rub the insect against the perch. This process acts to stun or kill the insect, removes venom and/or venom sacs, and may also remove the sting (Fry 1968, Higgins 2001). Further blows to the head are likely before the bird swallows the insect whole (Fry 1968, Higgins 2001). Non-venomous prey may be stunned or killed using blows to the head; but no further processing takes place (Fry 1968). Rubbing of the abdomen is reserved for venomous Hymenoptera prey only (Fry 1968). Shrikes (*Lanius spp*) maintain larders

and butchering points where they use similar techniques to process venomous prey for consumption (Tryjanowski et al. 2003). A degree of physiological immunity may reduce the effects of venom, while indigestible chitinous remnants are compressed and pelletized in the gizzard (Fry 1968, Saffer and Calver 1997, Tryjanowski et al. 2003) and caste approximately 1.5-4 hours after feeding (Higes et al. 2008). Despite numerous observational and behavioral studies undertaken, the behaviors described for bee-eaters and shrikes have not been seen in hihi (I. Castro, unpub. obs.).

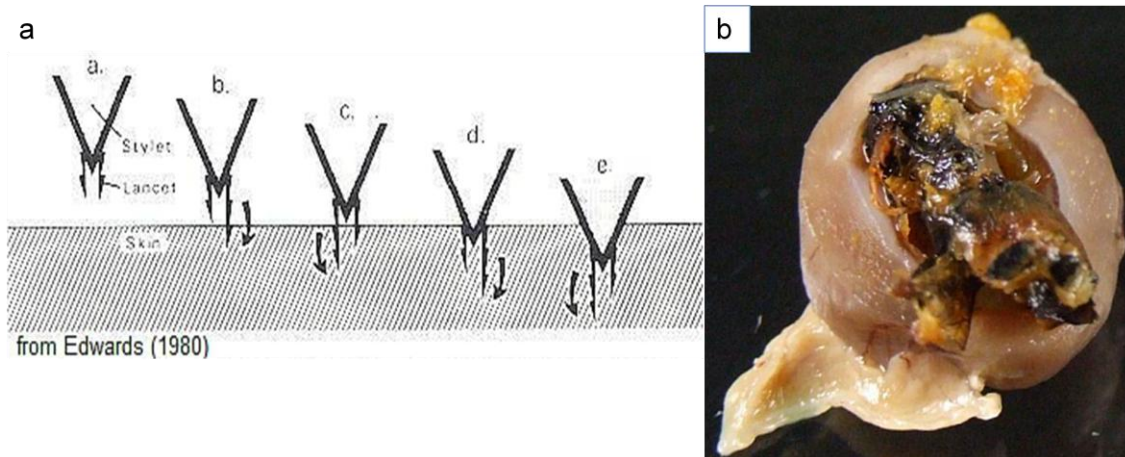


FIGURE 7.

a. Hymenoptera sting mechanism showing how the lancets pull the stylet into the flesh of the victim as venom is injected into the wound.

a. sting approaches skin; b. right lancet penetrates and barb holds in position; c. left lancet moves beyond position of right lancet, drawing sting further into tissue; d and e. alternating movements of the lancets draw stylet into flesh and venom is injected.

b. Honey bee (*Apis mellifera*) in the gizzard of a juvenile hihi that is suspected to have died from the effects of envenomation.

The structure of the gastrointestinal tract may predispose hihi to perforation. There is evidence that the diet of avian species influences the structure of the gastrointestinal tract, and that nectarivores have a smaller, less muscular gizzard because their diet comprises mainly nectar and soft-bodied flying insects (Richardson and Wooller 1986, 1990, Wooller et al. 1990). Those species that include predominantly insects in their diet (Richardson and Wooller 1986), or that are induced to eat chitinous insects (Ricklefs 1996), develop thick muscular gizzards in order to process their food adequately. Ricklefs (1996) suggests that the avian gut is structured to reflect the type of food consumed, and that these evolutionary adaptations may be related to the ecological environment. It is possible that nestling hihi develop a thicker, more muscular gizzard with age as their diet changes from predominantly soft insects and

nectar, to the omnivorous diet of the adult. Nestling and juvenile hihi may be more susceptible to traumatic ventriculitis than adults.

While the effect of traumatic ventriculitis caused by introduced Hymenoptera has been significant for the hihi population at Zealandia – Karori Sanctuary over the 2008-09 breeding season, further monitoring is needed to fully establish the impacts on hihi populations at this and other translocation sites. The distribution of bees and wasps throughout the North Island and adjacent offshore islands in New Zealand means hihi are now in contact with these species throughout their current range. Contact is further exacerbated by the need to supplementary feed hihi at all translocation sites which attracts nectar-feeding bees and wasps. Therefore the incidence of mortality due to insect-mediated traumatic ventriculitis may increase as a result of food provisioning. Seasonal availability of invertebrate prey may be a factor, particularly where bees and wasps are relatively more abundant than other prey species. Seasonal peaks in vespulid wasp numbers cause problems in forest habitats across New Zealand (Beggs 2000) but numbers have been successfully controlled in some ecological restoration areas (Saunders and Norton 2001).

Hihi foraging studies have focused on recording broad food types rather than the insect species utilized and there is little available data identifying the invertebrate prey taken. The structure of the gastrointestinal tract of hihi may provide further insight into the diet of these birds. There is a need to establish whether vespulid wasps are preyed upon because management options would change depending on the species consumed. Wasp control may require ongoing poison operations (Beggs 2000), whereas honey bee numbers might be adequately controlled by the use of bee-excluders with the sugar-water feeders, and relocating commercial hives away from hihi translocation sites. Investigations are needed to establish dietary components and further foraging studies will be required to determine the prey preferences and invertebrates utilized by hihi.

## **ACKNOWLEDGEMENTS**

Thanks to Raewyn Empson, Matu Booth, the staff and volunteers of Zealandia – Karori Sanctuary for collecting and submitting samples and data. Many thanks for the invaluable advice and technical expertise of Doug Hopcroft and staff at Manawatu Microscopy and Imaging Centre in producing the TEM and SEM photomicrographs. Thanks are due to John Brandon of Canaan Apiaries, Wanganui who supplied the honey bees and to Jane Kerridge of Medlab Wanganui who provided the facilities for much of the laboratory work. We acknowledge the outstanding technical abilities and expertise of IVAB's staff including Elaine Booker, Evelyn Lupton and Nicola Wallace,

and the members of the Ecology Group including Cleland Wallace, Tracy Harris, Paul Barrett and Maria Minor who were always willing to help. Particular mention is worthy of the tireless efforts and input from Ellen Schöner. Scholarship grants from the New Zealand Wildlife Health Centre Trust Research Fund, Graduate Women Manawatu Charitable Trust and J.P. Skipworth (Ecology) Fund were used to fund some of the work undertaken.

## LITERATURE CITED

- ALLEY, M. R. 2007. An oesophageal bee sting in a hihi, *Notiomystis cincta*. *Kokako* 14: 41.
- ALLEY, M. R., I. CASTRO, AND J. E. B. HUNTER. 1999. Aspergillosis in hihi (*Notiomystis cincta*) on Mokoia Island. *New Zealand veterinary journal* 47: 88-91.
- ANGEHR, G. R. 1984. Ecology and behaviour of the stitchbird with recommendations for management and future research. Internal Report to the New Zealand Wildlife Services. Department of Internal Affairs, Wellington, New Zealand. 62 pp.
- ARMSTRONG, D. P., I. CASTRO, J. C. ALLEY, B. FEENSTRA, AND J. K. PERROTT. 1999. Mortality and behaviour of hihi, an endangered New Zealand honeyeater, in the establishment phase following translocation. *Biological Conservation* 89: 329-339.
- ARMSTRONG, D. P., I. CASTRO, AND R. GRIFFITHS. 2007. Using adaptive management to determine requirements of re-introduced populations: The case of the New Zealand hihi. *Journal of Applied Ecology* 44: 953-962.
- ARMSTRONG, D. P., R. S. DAVIDSON, W. J. DIMOND, J. K. PERROTT, I. CASTRO, J. G. EWEN, R. GRIFFITHS, AND J. TAYLOR. 2002. Population dynamics of reintroduced forest birds on New Zealand islands. *Journal of Biogeography* 29: 609-621.
- ARMSTRONG, D. P., AND J. K. PERROTT. 2000. An experiment testing whether condition and survival are limited by food supply in a reintroduced hihi population. *Conservation Biology* 14: 1171.
- AWADHIYA, R. P., J. L. VEGAD, AND G. N. KOLTE. 1975. Traumatic ventriculitis in chickens. *Avian Diseases* 19: 696-699.
- BAILEY, T. A., J. KINNE, J. NALDO, C. D. SILVANOSE, AND J. C. HOWLETT. 2001. Two cases of ventricular foreign bodies in the kori bustard (*Ardeotis kori*). *Veterinary Record* 149: 187-188.
- BEGGS, J. R. 2000. Impact and control of introduced *Vespula* wasps in New Zealand. *In* Hymenoptera: Evolution, Biodiversity and Biological Control, A. D. AUSTIN, AND M. DOWTON, (eds.). CSIRO Publishing, Canberra, Australia. pp. 404-409
- BEGGS, J. R., AND J. S. REES. 1999. Restructuring of Lepidoptera communities by introduced *Vespula* wasps in a New Zealand beech forest. *Oecologia* 119: 565-571.
- CASTRO, I. 1995. Behavioural ecology and management of hihi (*Notiomystis cincta*), an endemic New Zealand honeyeater. Ph.D. Thesis. Massey University, Palmerston North, New Zealand.
- CASTRO, I., D. H. BRUNTON, K. M. MASON, B. EBERT, AND R. GRIFFITHS. 2003. Life history traits and food supplementation affect productivity in a translocated population of the endangered hihi (stitchbird, *Notiomystis cincta*). *Biological Conservation* 114: 271-280.



- CASTRO, I., AND A. W. ROBERTSON. 1997. Honeyeaters and the New Zealand forest flora: The utilisation and profitability of small flowers. *New Zealand Journal of Ecology* 21: 169-179.
- CAWDELL-SMITH, A. J., K. H. TODHUNTER, N. R. PERKINS, AND W. L. BRYDEN. 2009. Stage of pregnancy and foetal loss following exposure of mares to processionary caterpillars. *Journal of Equine Veterinary Science* 29: 339-340.
- CRAIG, J. L., A. M. STEWART, AND M. E. DOUGLAS. 1981. The foraging of New Zealand honeyeaters. *New Zealand Journal of Zoology* 8: 87-91.
- DADE, H. A. 1962. *Anatomy and Dissection of the Honeybee*. Bee Research Association, London, UK.
- DIAZ, J. H. 2005. The evolving global epidemiology, syndromic classification, management, and prevention of caterpillar envenoming. *American Journal of Tropical Medicine and Hygiene* 72: 347-357.
- DONOVAN, B. J. 1980. Interactions between native and introduced bees in New Zealand. *New Zealand Journal of Ecology* 3: 104-116.
- EDWARDS, R. 1980. *Social Wasps: Their Biology and Control*. Rentokil Limited, Felcourt, East Grinstead, UK.
- EMPSON, R., AND M. BOOTH. 2009. Zealandia - Karori Sanctuary Report to Hihi Recovery Group Meeting April 2009. Unpub. <http://www.hihiconservation.com> (accessed 16/11/2009). 3 pp.
- EMPSON, R., R. GOUDSWAARD, AND M. BOOTH. 2008. Report on hihi survival and productivity at Karori Sanctuary, 2008. Unpub. <http://www.hihiconservation.com> (accessed 16/11/2009). 4 pp.
- FRY, C. H. 1968. The recognition and treatment of venomous and non-venomous insects by small bee-eaters. *Ibis* 111: 23-29.
- GELIS, S. 2006. Evaluating and treating the gastrointestinal system. *In* *Clinical Avian Medicine*, G. J. HARRISON, AND T. L. LIGHTFOOT, (eds.). Spix Publishing, Palm Beach, Florida, USA. pp. 411-440
- GUPTA, B. N., AND A. L. TRAPP. 1971. Case History: Traumatic proventriculitis in a rhea (*Rhea americana*). *Avian Diseases* 15: 408-412.
- HARRIS, R. J., C. D. THOMAS, AND H. MOLLER. 1991. The influence of habitat use and foraging on the replacement of one introduced wasp species by another in New Zealand. *Ecological Entomology* 16: 441-448.
- HAZEN, K. C., AND S. A. HOWELL. 2003. *Candida*, *Cryptococcus* and other yeasts of medical importance. *In* *Manual of Clinical Microbiology*, P. R. MURRAY, E. J. BARON, J. H. JORGENSEN, M. A. PFALLER, AND R. H. YOLKEN, (eds.). American Society for Microbiology Press, Washington DC. pp. 1693-1711
- HIGES, M., R. MARTIN-HERNANDEZ, E. GARRIDO-BAILON, C. BOTIAS, P. GARCIA-PALENCIA, AND A. MEANA. 2008. Regurgitated pellets of *Merops apiaster* as fomites of infective *Nosema ceranae* (Microsporidia) spores. *Environmental Microbiology* 10: 1374-1379.
- HIGGINS, P. J. 2001. Family Meropidae bee-eaters. *In* *Handbook of Australian, New Zealand and Antarctic Birds*. Volume 4: Parrots to Dollarbird, P. J. HIGGINS, (ed.). Oxford University Press, Melbourne, Australia. pp. 1209-1225



- HIGGINS, P. J., J. M. PETER, AND W. K. STEELE. 2001. Stitchbird. *In* Handbook of Australian, New Zealand and Antarctic Birds. Volume 5: Tyrant-flycatchers to Chats, P. J. HIGGINS, J. M. PETER, AND W. K. STEELE, (eds.). Oxford University Press, Melbourne, Australia. pp. 954-966
- KASPARI, M., AND A. JOERN. 1993. Prey choice by three insectivorous grassland birds: Reevaluating opportunism. *Oikos* 68: 414-430.
- KREBS, J. R., AND M. I. AVERY. 1985. Central place foraging in the European bee-eater, *Merops apiaster*. *Journal of Animal Ecology* 54: 459-472.
- LOVEGROVE, T. 1985. Stitchbirds on Kapiti Island 1983-1985. Department of Lands and Survey, Wellington, New Zealand. 43 pp.
- LOW, M., AND T. PART. 2009. Patterns of mortality for each life-history stage in a population of the endangered New Zealand stitchbird. *Journal of Animal Ecology*.
- LUMEIJ, J. T. 1994. Gastroenterology. *In* Avian Medicine: Principles and Application, B. W. RITCHIE, G. J. HARRISON, AND L. R. HARRISON, (eds.). Wingers Publishing, Lake Worth, Florida, USA. pp. 482-521
- MILLER, D. 1974. Common Insects in New Zealand. A.H. & A.W. Reed, Wellington, New Zealand.
- OLIVER, W. R. B. 1955. New Zealand Birds. A.H. & A.W. Reed, Wellington, New Zealand.
- PERROTT, J. K. 1997. Effects of food supply and competition on the outcome of hihi (*Notiomystis cincta*) translocated to Mokoia Island. M.Sc. Thesis. Massey University, Palmerston North, New Zealand.
- . 2001. The ecology of *Aspergillus fumigatus* and implications for wildlife conservation in modified environments. Ph.D. Thesis. Massey University, Palmerston North.
- PERROTT, J. K., AND D. P. ARMSTRONG. 2000. Vegetation composition and phrenology of Mokoia Island, and implications for the reintroduced hihi population. *New Zealand Journal of Ecology* 24: 19-30.
- QUINN, P. J., M. E. CARTER, B. K. MARKEY, AND C. G. R. 1994. Clinical Veterinary Microbiology. Wolfe Publishing, London, UK.
- RAE, M. A. 2006. The diagnostic value of necropsy. *In* Clinical Avian Medicine, G. J. HARRISON, AND T. L. LIGHTFOOT, (eds.). Spix Publishing, Palm Beach, Florida, USA. pp. 661-678
- RASCH, G. 1985. The ecology of cavity nesting in the stitchbird (*Notiomystis cincta*). *New Zealand Journal of Zoology* 12: 637-642.
- RICHARDSON, K., AND R. WOOLLER. 1986. The structures of the gastrointestinal tracts of honeyeaters and other small birds in relation to their diets. *Australian Journal of Zoology* 34: 119-124.
- . 1990. Adaptations of the alimentary tract of some Australian lorikeets to a diet of pollen and nectar. *Australian Journal of Zoology* 38, 6: 581-586.
- RICKLEFS, R. E. 1996. Morphometry of the digestive tracts of some passerine birds. *The Condor* 98: 279-292.

- RODRIGUEZ-HERMOSA, J. I., A. CODENA-CAZADOR, J. M. SERVENT, A. MARTIN, J. GIRONES, AND E. GARSOT. 2008. Surgically treated perforations of the gastrointestinal tract caused by ingested foreign objects. *Colorectal Disease* 10: 701-707.
- SAFFER, V. M., AND M. C. CALVER. 1997. The size and type of prey taken by adult rainbow bee-eaters in the south-west of Australia. *Emu* 97: 329-332.
- SAUNDERS, A., AND D. A. NORTON. 2001. Ecological restoration at mainland islands in New Zealand. *Biological Conservation* 99: 109-119.
- SCHMIDT, R. E., D. R. REAVILL, AND D. N. PHALEN. 2003. Chapter 3: Gastrointestinal System and Pancreas. *In* Pathology of Pet and Avian Birds. Blackwell Publishing, Ames, Iowa, USA. pp. 41-65
- SEBASTIAN, M. M., W. V. BERNARD, T. W. RIDDLE, C. R. LATIMER, T. D. FITZGERALD, AND L. R. HARRISON. 2008. Review Paper: Mare reproductive loss syndrome. *Veterinary Pathology* 45: 710-722.
- SOMERVILLE, D. 2000. Honey bee nutrition and supplementary feeding. *In* W. E. SMITH, (ed.) *Agnote DA1/178*. NSW Agriculture, NSW, Australia. 8 pp.
- SPURR, E. B. 1996. Carbohydrate bait preferences of wasps (*Vespula vulgaris* and *V. germanica*) (Hymenoptera: Vespidae) in New Zealand. *New Zealand Journal of Zoology* 23: 315-324.
- TAYLOR, S., I. CASTRO, AND R. GRIFFITHS. 2005. Hihi/Stitchbird (*Notiomystis cincta*) Recovery Plan 2004-2009. Threatened Species Recovery Plan 54. Department of Conservation, Wellington, New Zealand. 31 pp.
- THOMAS, C. D., H. MOLLER, G. M. PLUNKETT, AND R. J. HARRIS. 1990. The prevalence of introduced *Vespula vulgaris* wasps in a New Zealand beech forest community. *New Zealand Journal of Ecology* 13: 63-72.
- TRYJANOWSKI, P., M. K. KARG, AND J. KARG. 2003. Diet composition and prey choice by the red-backed shrike *Lanius collurio* in western Poland. *Belgian Journal of Zoology* 133: 157-162.
- TWORT, F. W. 1924. An improved neutral red, light green double stain for staining animals, parasites, micro-organisms and tissues. *Journal of State Medicine* 32: 351.
- VELASCO, M. C. 2000. Candidiasis and cryptococcosis in birds. *Seminars in Avian and Exotic Pet Medicine* 9: 75-81.
- WICKWARE, A. B. 1945. Grasshoppers: A potential danger to turkeys. *Canadian Journal of Comparative Medicine* 9: 80-81.
- WOOLLER, R., K. RICHARDSON, AND D. WELLS. 1990. Allometric relationships of the gastrointestinal tracts of insectivorous passerine birds from Malaysia, New Guinea and Australia. *Australian Journal of Zoology* 38: 665-671.
- YOUNG, B. J. 1969. Staining of fungal hyphae in tissue sections. *Journal of Medical Laboratory Technology* 25: 342-346.

## 4 *Candida albicans* infection in free-living populations of hihi/stitchbird (*Notiomystis cincta*)

---

### Abstract

**AIM:** To investigate the carriage of *Candida albicans* in free-living hihi/stitchbird (*Notiomystis cincta*) populations and determine whether this organism impacts on nestling survival.

**METHODS:** Nestling mortality was investigated in a reintroduced population of the endangered, endemic hihi at Zealandia - Karori Sanctuary, Wellington, New Zealand. Oral and faecal samples were collected from live hihi nestlings for microbiological examination between October 2008 and April 2009. All hihi that died and could be recovered were submitted to the New Zealand Wildlife Health Centre (NZWHC) at Massey University for post-mortem examination. The results were compared to data obtained retrospectively from the National Wildlife Mortality (NWM) database for two other reintroduced hihi populations on Mokoia Island and Tiritiri Matangi Island.

**RESULTS:** Fifty chicks fledged from 82 eggs hatched during the 2008-09 breeding season at Karori. Thirty-four live nestlings were sampled from 11 nests and *Candida albicans* was isolated from gastrointestinal swabs of 13 live nestlings from four nest sites. Eight of these nestlings survived to fledge. Of the 32 hihi nestlings that died during the study period, 25 (78%) were recovered for necropsy. Histopathological examination revealed candidiasis was a factor in the deaths of four nestlings. An adult hihi that died during the study period at Karori was also found to have candidiasis. Retrospective analysis of data from the NWM database revealed candidiasis was a factor in the deaths of five nestlings aged between 1 - 10 days from Mokoia Island, and of three nestlings <5 days old and one adult from Tiritiri Matangi Island.

**CONCLUSIONS:** Some hihi appear to be carriers of *Candida albicans* and vertical transmission of this organism from parent to offspring may occur. Although some colonised nestlings developed ventriculitis lesions associated with *Candida*, others survived till fledging and may become carriers within the population.

**KEYWORDS:** *Candida albicans*, hihi, stitchbird, *Notiomystis cincta*, ventriculitis.

## Introduction

*Candida albicans* has global distribution as an environmental contaminant and is a commensal inhabitant of the epithelial mucosa and the gastrointestinal tract of many vertebrate species (Velasco 2000). Along with the normal microbial flora, this dimorphic yeast colonises the mucous membranes of many healthy individuals but *Candida albicans* has the potential to induce disease involving most tissues and organs (Shepherd et al 1985). Immune suppression or disturbances to the normal bacterial flora of the host may predispose to acute or chronic fungal disease in colonised animals (Dahlhausen 2006; Alley et al 2009). Colonisation itself may predispose to disease (Castagnola and Buratti 2009; Concia et al 2009); also the colonised host may become a carrier or latent source of infection (Buck 1986; Cafarchia et al 2006). The incidence of candidiasis (alternatively called candidosis, moniliasis, or thrush) is increasing (Shepherd et al 1985) and *Candida albicans* is recognised worldwide as a leading cause of nosocomial infections (Brecht et al 2009; Ramage et al 2009). Historically regarded as an opportunistic or secondary pathogen, *Candida albicans* is now known to cause primary disease in healthy individuals (Vieira and Acqua Coutinho 2009; Zhu and Filler 2010). Increased virulence of the microorganism and compromised immunocompetence in many host species have been described (Ramage et al 2009) and, given that the incidence of disease is increasing, *Candida albicans* may be regarded as an emerging pathogen (Daszak et al 2000). A number of virulence factors that are associated with the pathogenicity of *Candida albicans* include dimorphism (the yeast to mycelium transition) (Shepherd et al 1985), secretion of hydrolytic enzymes and the ability to adhere to epithelial surfaces (Vieira and Acqua Coutinho 2009; Zhu and Filler 2010).

Alone, or in combination with other microorganisms, *Candida albicans* has the ability to adhere to many surfaces, forming complex structures known as biofilms (Ramage et al 2009; Thein et al 2009). This trait has become well-described in the medical journals, as implanted medical devices such as prostheses, valves and in-dwelling catheters may become colonised and a source of ongoing infections in compromised patients (Nett and Andes 2006). Biofilms are complex three-dimensional matrix structures formed by a mixture of hyphae, pseudohyphae and vegetative yeast cells interacting synergistically to adhere, colonise and spread across a given surface (Ramage et al 2009). Because biofilms actively protect themselves from the host immune system, frequently the only means to remove the source of infection is to remove the contaminated item, thus subjecting the patient to further surgical procedures and increasing risk factors (Ramage et al 2009). Research has shown that biofilms may be more likely to develop in the presence of cellular or body fluids, particularly where some movement or flow occurs (Nett and Andes 2006). Flow itself

may facilitate further dissemination of the microorganisms for example allowing colonisation to occur systemically via blood vessels (Concia et al 2009). Mycelial growth may also penetrate with the aid of secreted hydrolytic enzymes, and a common finding in candidiasis is the infiltration into and through cellular layers of the host epithelium to infiltrate underlying tissues and organs (Zhu and Filler 2010).

Carbohydrate substrates are known to facilitate the growth of many microorganisms, and *Candida spp* are frequently found as food contaminants (Verran et al 2008). It is thought that cellular exudates and body fluids may interact in a similar fashion to carbohydrates in stimulating growth of *Candida albicans* (Ramage et al 2009). Just as biofilms are found to adhere to and proliferate in inanimate prosthetic devices (Ramage et al 2009), so too biofilms may occur on the surfaces used for preparation and storage of food (Verran et al 2008). For this reason strict hygiene is necessary to control and prevent contamination of foodstuffs and the containers used to store or present the foods (Verran et al 2008).

Hihi/stitchbirds (*Notiomystis cincta*) are endemic, endangered passerines that were formerly widespread throughout the North Island of New Zealand, but are now confined to a single remnant population on Hauturu (Little Barrier Island) (Oliver 1955) and translocated populations on two offshore islands and three mainland sites. Hihi are cavity nesters and because regenerating forest does not provide sufficient natural nesting sites, nest boxes are provided (Taylor et al 2005) for most of the reintroduced populations. Although the male parent may assist in provisioning the young, the female parent takes sole responsibility for nest building and incubating (Castro et al 2003), and generally remains site specific throughout the season (Castro 1995). Hihi rear up to three clutches per year.

Disease, along with habitat destruction and the effects of introduced competitors and predators, is thought to have contributed to the catastrophic decline of hihi following European colonisation (Angehr 1984). Disease has been included among the factors considered to limit population establishment at some translocation sites (Higgins et al 2001; Taylor et al 2005). For example, hihi were removed from Mokoia Island because the high mortality of adult birds, at least partially caused by aspergillosis (Alley et al 1999), compromised the viability of this population (Armstrong et al 2007). Factors limiting the populations vary, and food availability is the only factor that has been experimentally tested and proven to influence population growth (Castro et al 2003; Armstrong et al 2007). Hihi are omnivorous, feeding on a range of invertebrate prey, nectar and forest fruits (Craig et al 1981; Angehr 1984; Lovegrove 1985), and seasonal variations in foraging behaviour reflect food availability throughout the year (Angehr 1984; Lovegrove 1985; Castro 1995; Perrott 1997). All translocated

populations to date require ongoing management to remain viable, and providing a high energy food supplement, usually sugar-water, is one strategy used (Taylor et al 2005).

The aim of this study was to investigate the carriage of *Candida albicans* in free-living hihi/stitchbird (*Notiomystis cincta*) populations and determine whether this organism impacts on nestling survival.

## Methods

### Study populations

Zealandia – Karori Sanctuary (41°17'S, 174°44'E) is a mainland island sanctuary situated in suburban Wellington, on the south coast of New Zealand's North Island. The 225ha reserve has been subject to an intensive revegetation programme, and is surrounded by a mammalian predator proof fence. Ecological restoration has increased the available habitat for native species, while translocations of rare or threatened endemic fauna have further increased biodiversity. Habitat modification and reintroduction programmes increase the risk of disease outbreaks as ecological change and changing the composition of the flora and fauna impacts on both pathogens and host species (Daszak et al 2000). Naive hosts and novel pathogens may be brought into close contact, the effects of which may be further exacerbated by environmental stress factors (Tompkins and Poulin 2006).

From February to May 2005, reintroduction of hihi began with the release of 60 (55 juvenile and five adult) birds sourced from Tiritiri Matangi Island (Empson et al 2008). A similar cohort was released in 2006, while additional smaller hihi introductions over subsequent years have helped to increase the population (Empson et al 2008). Management of this population includes colour banding all individuals for monitoring survival and breeding success, as well as provision of nest boxes and supplementary food (sugar-water solution, Wombaroo™ Insectivore mix) (Empson and Booth 2009).

During the 2008-09 hihi breeding season at Zealandia – Karori Sanctuary, all hihi used the nest boxes provided for breeding purposes, allowing ready access to the nest contents. Karori staff and volunteers closely monitored the hihi throughout the breeding season and ensured feeders were cleaned and fresh solution provided every second day (Taylor and Castro 2000). Data from feeder stations and nest boxes were collected and maintained as the progress for each clutch was recorded from nest building, through egg laying, to fledging. Nest boxes were checked every 2-3 days, and daily during periods of change such as when eggs were due to hatch, or nestlings

due to fledge. Further checks were made when sampling was scheduled. The chicks were considered to be nestlings from hatching to fledging, a period of 28-30 days (Higgins et al 2001). Infertile and abandoned eggs and dead chicks were removed from nest boxes, encouraging females to nest again. Dead birds recovered for necropsy were submitted to the New Zealand Wildlife Health Centre (NZWHC) at Massey University, Palmerston North.

Sampling of live nestlings was carried out from hatching until banding at approximately 20 days of age, and nestlings were sampled at 5-9 day intervals (a maximum of three times). Each nestling was weighed in an open ziplock bag using a 100g Pesola spring balance, and oral swabs and faeces or cloacal swabs were collected from each. Sample collection was approved by the Massey University Animal Ethics Committee, Palmerston North (08/96) and the Department of Conservation (DoC), Wellington Conservancy (Low Impact Research Permit Number WE/346/RES).

Samples were collected from 34 live nestlings at 11 nest boxes and from 25 (78%) of the 32 nestlings that died. Gastrointestinal (oral and faecal or cloacal) swabs from live nestlings were collected into Amies transport medium for microbiology. Swabs were refrigerated and transported on ice. As soon as possible following the recovery of dead nestlings oral and cloacal swabs were collected as above, before preserving the carcass for histopathology. This protocol minimised post mortem changes and reduced the amount of tissue autolysis and bacterial overgrowth that may have occurred had the carcasses been kept chilled or frozen prior to transportation.

Mokoia Island (38°06'S, 174°55'E) is a 135ha island situated in Lake Rotorua, a freshwater lake in the central North Island of New Zealand. From the outset, hihi reintroduced to Mokoia Island from Hauturu in 1994 were subject to monitoring and adaptive management (Armstrong et al 2007) that included seasonal provisioning with sugar-water or Wombaroo™ (Castro et al 2003). Mokoia has a long history associated with human colonisation and forest clearance that has resulted in a highly modified habitat with high environmental levels of *Aspergillus fumigatus* spores present (Perrott 2001). Mortality in adult birds was due to aspergillosis (Alley et al 1999), a problem that could not be resolved through management, and that compromised the viability of the population, therefore all surviving hihi were removed from the island in 2002 (Armstrong et al 2007).

Tiritiri Matangi Island (36°36'S, 174°53'E) is a 220ha island in the Hauraki Gulf 3.5km off the Whangaparoa Peninsula near Auckland in the north of the North Island, New Zealand. Subject to close monitoring and adaptive management, hihi translocated from Hauturu during 1995 and 1996 have established successfully (Armstrong et al

2002; Low et al 2007), and birds from this population are harvested to provide founder stock for new reintroductions. Hihi at this site have year round access to sugar-water feeders (Low and Part 2009).

Data from archived cases held in the National Wildlife Mortality (NWM) database at Massey University have been used in this study. Nestlings and adults that died on Mokoia Island from 1995-98 underwent post-mortem examination as part of another study (I. Castro, unpub. data). Results from Mokoia during this period implicated candidiasis in the death of some nestlings (I. Castro, unpub. data). Feeder stations were considered as a possible source of *Candida spp* and food samples were collected for fungal culture after varying times of food exposure (at 24 hours and greater than 48 hours). No yeasts or *Candida spp* were isolated although some fungal growth was observed in food substrates that were more than two days old (Alley et al 1999). However, food was never available to the birds for longer than two days because best practice indicates that feeders need to be changed every 48 hours and that used feeders must be disinfected after each use (Taylor and Castro 2000). These strict guidelines are followed at all hihi translocation sites. Dead hihi recovered from Tiritiri Matangi Island (1998 – 2002) were fixed in 10% buffered formalin and submitted to NZWHC by DoC staff as part of routine management of these populations. The cause of death was determined by necropsy and histopathological examination.

## **Microbiology**

Oral and faecal or cloacal swabs, collected from live and dead hihi at Karori into Amies transport medium (Copan Venturi Transystem, Amies Agar Gel Medium without Charcoal, Fort Richard Laboratories, New Zealand), were cultured using routine methods for bacterial and fungal isolation (Quinn et al 1994). Bacterial culture was used to estimate levels of normal gastrointestinal flora in these birds and to screen for the presence of pathogens. Columbia 5% Sheep Blood agar (CBA) (Fort Richard Laboratories, New Zealand) was inoculated and incubated aerobically at 35°C for 3 days. Sabouraud's Dextrose agar (SDA) with antibiotics (Fort Richard Laboratories, New Zealand) was inoculated and incubated aerobically at 25°C for 10 days to screen for *Candida spp* and *Aspergillus spp*. Colonies of interest were subcultured onto SDA and CBA for purity and identification by colonial characteristics and Gram stain morphology. Diagnostic tests including germ tube production (Quinn et al 1994) and specific growth characteristics on CHROMagar™ *Candida* agar (Fort Richard Laboratories, New Zealand) (Hazen and Howell 2003) were undertaken where necessary.



*Germ tube test* - a light inoculum of yeast in plasma was incubated for two hours at 37°C and examined by phase contrast microscopy for the presence of Germ tubes, which are lateral extensions from the yeast cells that show no constriction where they meet the parent cell. This is characteristic of *Candida albicans* and a positive result is sufficient to make a presumptive identification (Quinn et al 1994).

*Growth on BBL™ CHROMagar™ Candida agar* - following the manufacturer's instructions, plates were inoculated to yield single colonies of yeasts and incubated aerobically at 35°C for 36-48 hours. Specific enzymes release chromogenic breakdown products that result in light-medium green colonies that confirm the presence of *Candida albicans* (Hazen and Howell 2003).

### **Histopathology**

For each of the dead nestlings, cause of death was diagnosed by necropsy examination and histopathology. Dead featherless nestlings were fixed whole in 10% buffered formalin and feathered chicks were incised down the ventral midline before fixation. Neonates and very small nestlings were cut in 3-5mm transverse sections along the length of the body, so that the whole bird was processed. For larger birds, four to five 3-5mm cross sections were obtained along the length of the body. Sections were routinely processed and embedded in paraffin blocks from which 5µm sections were cut and stained using haematoxylin and eosin (H&E) staining techniques. Serial cross sections ensured that all organs and body systems could be systematically assessed microscopically. Following microscopic examination, further sections were cut to access tissues or lesions deeper in the blocks, or to confirm the presence of bacteria or fungi using Gram-Twort (Twort 1924) or Young's fungal (Young 1969) stains.

## **Results**

### **Zealandia – Karori Sanctuary**

During the 2008-09 breeding season, 82 of 146 eggs hatched and 50 chicks fledged (Empson and Booth 2009). A total of 32 hihi nestlings died during the breeding season and 25 (78%) were recovered for necropsy examination. Sampling of live nestlings began in December 2008 and 34 nestlings from 11 nests were sampled until the final chicks fledged in March 2009. *Candida albicans* was isolated from 13 live nestlings at four nest sites only (Table 1); of these five nestlings died and eight survived to fledge. A further seven chicks from these nest sites fledged but were not tested. Once isolated, *Candida albicans* was recovered from all siblings that were tested within a

nest and nestlings in subsequent clutches raised by these parents also tested positive for this organism.

**Table 1.** *Candida albicans* was associated with ventriculitis in hihi nestlings from four nest sites at Zealandia – Karori Sanctuary. *Candida albicans* was isolated from thirteen live nestlings and the pathological lesions in four nestlings that died showed evidence of candidiasis.

Clutch	Nestbox	Eggs	Hatched	Fledged	Histo <sup>1</sup>	Micro <sup>2</sup>
1	26	4	2	0	0/2 <sup>a</sup>	0/2 <sup>b</sup>
	39	4	3	3		Not tested
	42	4	4	0	2/4	2/2
	129	4	0			
2	26	5	4	4		Not tested
	39	4	3	3		3/3
	42	0				
	129	4	3	1	0/2	1/1
3	26	4	4	4		4/4
	39	0	(mother died)	died)	(1/1)	(1/1)
	42	0				
	129	3	3	0	2/3	3/3
<b>Total</b>		36	26	15	4/11	13/15

<sup>1</sup> Pathological lesions associated with candidiasis include ventriculitis

<sup>a</sup> Number birds with lesions/number examined

<sup>2</sup> *Candida albicans* isolated from oral, faecal or cloacal swabs

<sup>b</sup> Number birds *Candida albicans* POSITIVE/number tested

( ) Not included in nestling totals

Histopathological examination revealed candidiasis was a factor in the deaths of four nestlings (16% of the dead nestlings recovered from Karori), and *Candida* infiltration appeared to be secondary to traumatic ventricular lesions in three of the four nestlings. Microscopic examination of the gizzard mucosa revealed areas of epithelial cell necrosis and mixed predominantly mononuclear inflammatory cell infiltration of the glandular mucosa, with overlying localised areas of severe disruption to the koilin layer (Figure 1). Within the lesions, clusters of pale basophilic spherical and ovoid budding yeast-like organisms (blastospores) 10-15µm diameter were seen, sometimes mixed with elongated pseudo-hyphae fungal elements (Figure 2). Erosion of the mucosa was seen in some cases, while in others granulomatous lesions were associated with insect remnants in the ventricular wall and serosa (Figure 3). The diagnosis of candidiasis was based on the presence of blastospores and infiltrating hyphae which were non-septate and typical of *Candida spp* (Hazen and Howell 2003)

and microbiological culture of gastrointestinal swabs (Table 1) confirmed the presence of *Candida albicans*.

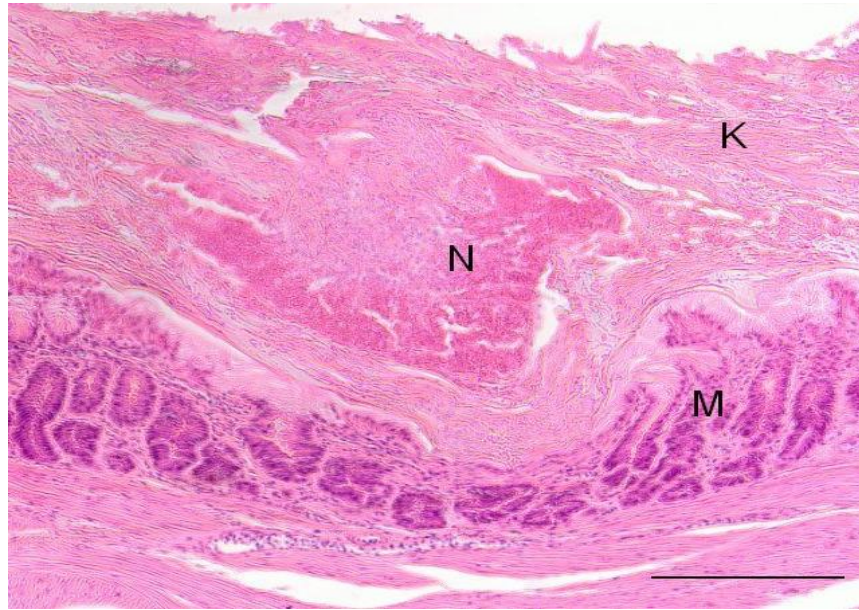


Figure 1 Light photomicrograph of the mucosa of the ventriculus of chick C from Karori nestbox 42 showing a severely thickened koilin layer (K) with extensive invasion of *Candida* hyphae that is also infiltrating into the underlying mucosal layer (M). An area of inflammatory response is focussed on necrotic debris in the centre of the section (N). (H&E; bar=100µm)

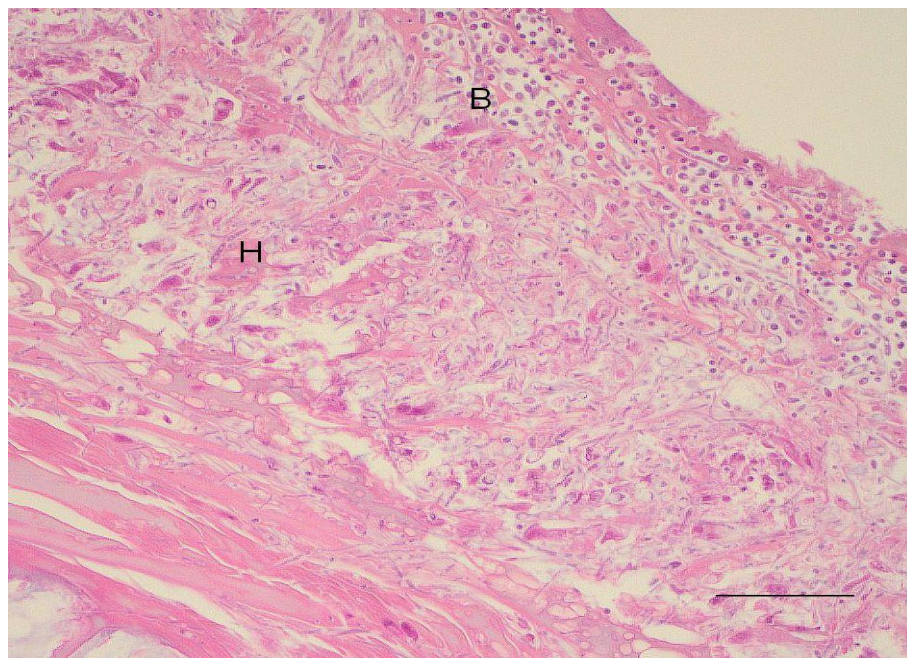


Figure 2 Light photomicrograph of the mucosa of the ventriculus of chick B from Karori nestbox 42 shows blastospores (B) within the koilin layer and extensive invasion of *Candida* hyphae (H) infiltrating into the underlying mucosal layer. (H&E; bar=50µm)

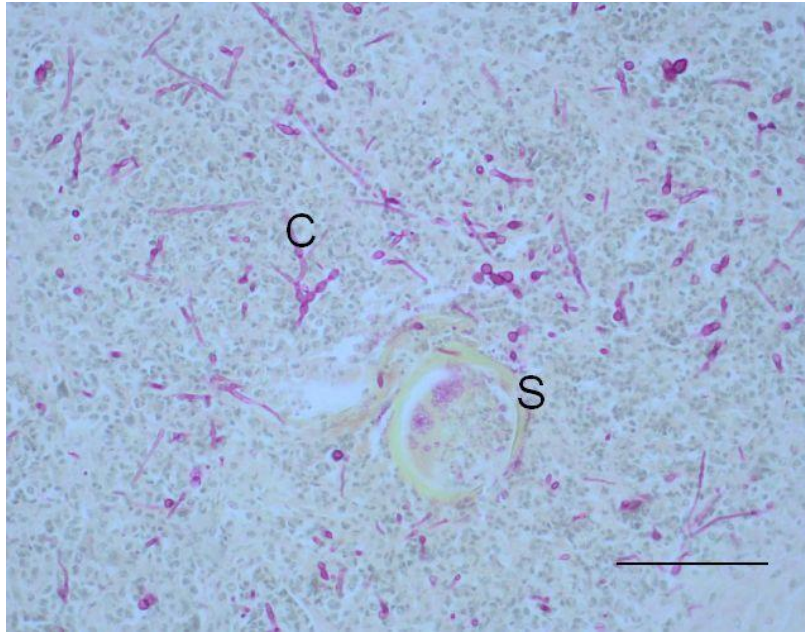


Figure 3 Light photomicrograph of a granuloma on the serosal surface of the ventriculus of chick B from Karori nestbox 129 showing budding *Candida* pseudohyphae (C) and an associated insect remnant (S). (Young's fungal stain; bar=50µm)

Necropsy examination of an adult female hihi that died during the breeding season also revealed histopathological lesions consistent with traumatic ventriculitis and candidiasis. Having successfully reared two clutches of three chicks to fledging, this adult bird was captured and treated for a traumatic leg injury, but died in captivity. Antibiotic treatment for the leg injury may have facilitated candidiasis in the adult female; however prior to fledging all three of the second clutch nestlings returned positive cultures for *Candida albicans* (Table 1) and colonisation of the nestlings would have occurred before the female was injured. Oral and cloacal swabs collected post mortem from the female were positive for *Candida albicans* suggesting that this female (from nestbox 39) may have been a carrier of *Candida albicans*.

### **Mokoia Island and Tiritiri Matangi Island**

Records of hihi mortalities from the NWM database in which candidiasis was diagnosed were reviewed. It was confirmed that candidiasis was a factor in the deaths of five nestlings aged between 1 - 10 days from Mokoia Island, and in three nestlings < 5 days old as well as one adult bird from Tiritiri Matangi Island (Table 2). The deaths on Mokoia occurred in January, November and December 1997 and the offspring of a single female were affected over two breeding seasons. They involved one second clutch nestling in 1996-97 and two first clutch nestlings together with two second clutch nestlings from 1997-98. The nestling deaths on Tiritiri Matangi occurred in

March and November 1998 and also affected chicks from two breeding seasons; one nestling from 1997-98 and two first clutch siblings during 1998-99. In January 2002, an adult female from Tiritiri Matangi died with lesions of candidiasis, aspergillosis, and a gizzard nematode all of which were thought to have contributed to the bird's demise. As in the Karori cases, it was concluded that candidiasis affected more than one nestling at a given nest and if the female parent was a carrier then the offspring in subsequent clutches would also be affected.

**Table 2. Mortalities associated with *Candida ventriculitis* in nine hihi from Mokoia Island (Mok) and Tiritiri Matangi Island (Tiri) 1996-2002**

Site	Season	Clutch	Nestbox	Age	Histo <sup>1</sup>	Other <sup>2</sup>
Mok	1996-7	2	60	10 days	+++	necrotising splenitis
Mok	1997-8	1	60	neonate	+++	head trauma
Mok	1997-8	1	60	neonate	+++	
Mok	1997-8	2	60	1 day	++	cutaneous mites
Mok	1997-8	2	60	1 day	++	
Tiri	1997-8			<5 days	+	bacterial rhinitis/sinusitis
Tiri	1998-9	1	B1/1	neonate	+++	
Tiri	1998-9	1	B1/1	<2 days	++	
Tiri	2001-2			adult	+++	aspergillosis, nematode

<sup>1</sup> Pathological lesions showed ventriculitis associated with candidiasis

<sup>2</sup> Other diagnoses associated with cause of death

Lesion Score: Mild = +, Moderate = ++, Severe = +++

The pathological lesions in the affected chicks were similar to those in the Karori cases and ranged in severity from a localised superficial ventriculitis to severe and extensive hyperkeratosis of the koilin layer, inflammatory necrosis of the glandular mucosa and irregular infiltration of the underlying sub-mucosa by lymphocytes and macrophages. The lesions contained large numbers of non-septate pseudohyphae and yeast-like blastospores suggestive of *Candida albicans* (Figure 4).

## Discussion

Candidiasis, a disease commonly seen in debilitated or immunosuppressed captive passerines (Rae 2006), was found to be associated with mortality in nestlings of free-living passerines at Zealandia – Karori Sanctuary and on Mokoia and Tiritiri Matangi Islands. In the Karori population, *Candida ventriculitis* was implicated in 16% of the nestling mortalities. *Candida albicans* was also isolated from the gastrointestinal tract of Karori nestlings that showed no clinical symptoms of disease and survived to fledging, although the ultimate fate of these birds is unknown.



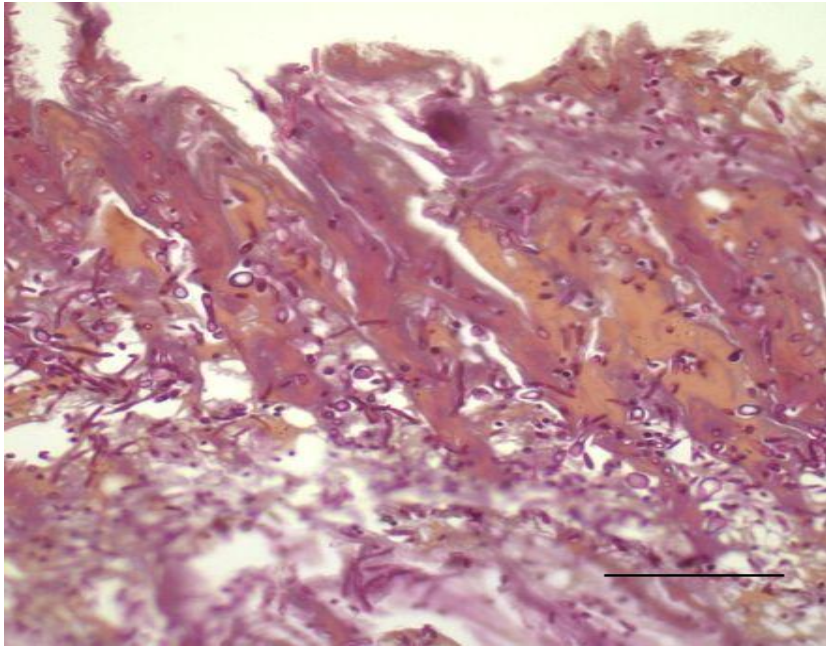


Figure 4 Light photomicrograph of the mucosa of the ventriculus of chick 1 from Mokoia nestbox 60 showing extensive invasion by *Candida* pseudohyphae which are forming yeast-like buds throughout the mucosa. (Young's fungal stain; bar=50µm)

*Candida* infections of the digestive tract that are commonly associated with birds in captivity affect the oesophagus, crop and ventriculus (Velasco 2000). Crop stasis leads to ill-thrift and emaciation and clinical signs include failure to thrive, regurgitation, and anorexia (Reavill and Schmidt 2000). The mucus membranes may show mild white streaking to necrotic yellowish plaques (Reavill and Schmidt 2000) progressing to the distinctive thickening and roughened 'terry-towelling' appearance seen in chronic crop infections (Rae 2006), and diagnosis is confirmed by microscopy and culture. Gizzard infections are difficult to diagnose as often there are no apparent clinical signs before death occurs, and the gross appearance is unremarkable (Reavill and Schmidt 2000; Rae 2006). On histological examination budding yeasts, hyphae and blastospores seen within the koilin layer indicate *Candida* proliferation and infiltration (Rae 2006). *Candida albicans* produces proteinases that break down keratin and collagen to cause disruption of the koilin layer (Tsai et al 1994) contributing to the disease process (Vieira and Acqua Coutinho 2009).

The immune competence of the host, in particular the cell-mediated immune response and the integrity of the normal bacterial flora associated with the mucous membranes, are the first lines of defence in protecting against opportunistic pathogens such as *Candida albicans* (Shepherd et al 1985). Because these defences are immature in neonates they may be more susceptible to *Candida* infections (Castagnola and Buratti 2009) since the immune system is still developing and normal flora is not well established (Toft 1991; Shepherd, 1985). Factors that predispose to candidiasis also

cause immune suppression or disruption to the normal microbial flora. Parasitism, malnutrition, Vitamin A deficiency, other infectious diseases, and antibiotic therapy have all been implicated (Velasco 2000; Dahlhausen 2006). Stress is frequently associated with *Candida* infections and may be related to captivity, poor diet, poor hygiene and overcrowding (Velasco 2000; Dahlhausen 2006).

In most cases, superficial lesions on the mucosal surfaces are the focus for the dissemination of *Candida* which can then progress to severe localised invasive disease, but direct entry to the bloodstream is also possible following some traumatic events (Shepherd et al 1985). Mortality involving candidiasis in the two adult birds from Karori and Tiritiri Matangi was associated with ventricular trauma or infectious disease respectively, and nestling deaths at Mokoia and Tiritiri Matangi also involved other disease processes in most cases (Table 2). Sharp chitinous insect remnants (e.g. wasps, bees) penetrating the gizzard mucosa and creating pathways for microbial flora to infiltrate were a feature of many of the nestling deaths at Karori but not those on Mokoia or Tiritiri Matangi Islands. For each of the dead hihi nestlings the ventriculus appeared to be the focus of infection from which *Candida spp* disseminated.

There have been few studies of the effect of fungi on birds, and the relationships between microorganisms and avian species are complex (Goodenough and Stallwood 2010). A survey to investigate the normal flora of bustards concluded that *Candida albicans* is not normally present in these species (*Chlamydotis undulate*, *Ardeotis kori*, *Eupodotis ruficrista*), and was only isolated from a lesion in a sick bird (D'Aloia et al 1996). Although *Candida albicans* is recognised as a common infectious disease in captive populations (Reavill and Schmidt 2000), its prevalence and disease status in free-ranging wild birds is seldom reported (Friend 1999; Cafarchia et al 2006). In a European study investigating the role of migratory birds as carriers of pathogenic organisms, *Candida albicans* was isolated from the cloacae of woodcock (*Scolopax rusticola*) (1.2%), teal (*Anas crecca*) (1.7%), and collared doves (*Streptopelia decaocto*) (1.9%), but was not recovered from four other species tested (Cafarchia et al 2006). Another study in the USA isolated *Candida albicans* from 78% of fresh seagull faeces collected along the Connecticut coastline and in 38% collected from West-Central and Southern Florida (Buck 1986). A study of the microbial flora present in the nests of blue tit and great tit showed *Candida albicans* was present in 10% of the nests sampled (Goodenough and Stallwood 2010). The intestinal microflora of wild birds is influenced by diet and habitat (Cafarchia et al 2006; Goodenough and Stallwood 2010) and these studies suggest that the prevalence of *Candida albicans* may vary considerably with respect to site and species.

Samples collected from nestlings at Karori showed that *Candida albicans* was recovered from all siblings within a nest, and nestlings from subsequent clutches at the same nest also returned positive cultures for the duration of the breeding season. Since female hihi remain site specific, it is significant that *Candida albicans* was also recovered from the female parent at one nest. A case involving the female parent and broods of offspring over two breeding seasons was seen at Mokoia. The dissemination of pathogens from parents to offspring during regurgitative feeding has been proven in pigeons (Tsai et al 1994), finches (Macwhirter 1994; Sandmeier and Coutteel 2006) and psittacines (Dahlhausen 2006), Hihi (Angehr 1984; Higgins et al 2001) are passerines that provision nestlings by regurgitation and therefore *Candida albicans* may be transferred vertically from the parent bird to the offspring during feeding.

High carbohydrate diets have been associated with candidiasis in pigeons (Tsai et al 1994). A disease outbreak caused crop impaction and candidiasis in about 1000 pigeon nestlings hand-fed a grower diet high in carbohydrates, resulting in 100% morbidity and 50% mortality (Tsai et al 1994). Crop milk, provided by the parent pigeons, contains virtually no carbohydrates and an experimental study confirmed that feeding a high carbohydrate diet caused candidiasis in nestlings exposed to *Candida albicans* (Tsai et al 1994). Yeasts readily utilise carbohydrates for optimal growth and proliferation and where carbohydrates are limited, this may effectively starve the *Candida*. Therefore limiting carbohydrate intake in host species may reduce the spread and limit the impact of disease associated with *Candida albicans* (Velasco 2000). Provisioning translocated populations of hihi with carbohydrates such as sugar-water may therefore actively facilitate *Candida albicans* colonisation and infection of the gastrointestinal tract, affecting both the parent birds that use the feeders, and their offspring.

Work done on the Mokoia hihi population had shown evidence that candidiasis was implicated in the deaths of hihi. Cultures from feeder station substrates at Mokoia were all negative for *Candida spp* (Alley et al 1999). Although feeder stations and substrates were not cultured directly at Karori, there was no evidence that the supplementary food was a major source of contamination for this population. Because different substrates (sugar-water versus Wombaroo™) were fed at opposite ends of the valley and very strict hygiene protocols were in place, it was considered unlikely that gross contamination would occur. It was anticipated that evidence of contamination and dissemination of *Candida spp* from the feeders would be detected by oral swabs, as evidence of transient colonisation of the oral cavity at least should be apparent in nestlings provisioned with *Candida*-contaminated feed. Also transient colonisation would manifest across a range of nestlings at different nest sites and there was no evidence that this was the case. A single exposure to food contaminated



with *Candida albicans* was sufficient to induce carrier status, but not disease, in an immature wild gull (*Larus sp*) (Buck 1986) and suggests that other factors influence disease establishment. This is consistent with studies of wild populations which found that birds may be asymptomatic carriers of *Candida albicans* (Buck 1986; Cafarchia et al 2006).

Because positive culture results were seen from all siblings at a given nest and in subsequent broods raised by the same parent birds, and the cultures remained positive for *Candida albicans*, the culture results suggested a 'nest effect'. Further, the nestlings with *Candida albicans* detected in gastrointestinal swabs that subsequently died showed evidence of disseminated candidiasis on histological examination.

Histological evidence of candidiasis was seen following necropsy of female parent hihi whose offspring were known to be colonised by *Candida albicans*, and gastrointestinal swabs from the female from Karori were also positive for *Candida albicans*. This suggests vertical transfer from the parent bird(s) to their offspring, rather than mass contamination emanating from the food source i.e. supplementary feeders.

Gastrointestinal (oral and faecal or cloacal) swabs were collected specifically because it allowed very small chicks/neonates to be sampled with minimal risk of harm. It was hoped that the swabs would be useful as a relatively non-invasive procedure to assess colonisation/carrier status. The methodology has proven to be robust in so far as the culture results correlated well with the histopathology results obtained. Further work will be required to confirm these results. However this study indicates that it is possible to use gastrointestinal swabs to directly screen for the presence of *Candida albicans* in hihi populations and that this may determine carrier status and/or the potential for infection within the population.

The data collected over a single breeding season from Zealandia – Karori Sanctuary is insufficient to fully understand the epidemiology of *Candida albicans* in this population. The retrospective data from the two other populations, collected a number of years earlier, was not collected for the purposes of this epidemiological study. Because all three of the populations under investigation used nest boxes and were intensively monitored, a high percentage of dead nestlings were recovered for necropsy. However, after fledging very few free-living birds that die are recovered and therefore it was not possible to establish the ultimate fate of most of the infected birds.

This report identifies a number of factors that may be associated with an increased risk of candidiasis in hihi populations. These include the link that exists between

provisioning with high energy carbohydrates and *Candida* colonisation of the alimentary tract; the role of regurgitative feeding in transmission of *Candida albicans* from parent birds to nestlings and the likelihood that traumatic ventriculitis and other diseases reduce host immunity and allow *Candida albicans* to disseminate and invade local tissues. In addition hihi are subject to nutritional and social stressors, especially during the highly competitive breeding season, but also as a result of inter-specific competition for food resources. Additional studies are therefore needed to further define how each of these factors impacts on the prevalence of *Candida albicans* and disease incidence for each translocated hihi population.

### **Acknowledgements**

Thanks to Raewyn Empson, Matu Booth, the staff and volunteers of Zealandia – Karori Sanctuary for collecting and submitting samples and data, and thanks to the volunteers, research workers and Department of Conservation staff, including Rosalie Stamp, Shaarina Boyd and Richard Griffiths, who were involved with managing the hihi populations on Mokoia and Tiritiri Matangi Islands and who submitted samples used in this survey. Thanks to Jane Kerridge of Medlab Wanganui who provided the facilities for much of the laboratory work. We acknowledge the outstanding technical help from IVAB's staff including Elaine Booker, Evelyn Lupton and Nicola Wallace. Scholarship grants from the New Zealand Wildlife Health Centre Trust Research Fund, Graduate Women Manawatu Charitable Trust and J.P. Skipworth (Ecology) Fund were used to fund some of the work undertaken.

## References

- Alley MR, Castro I, Hunter JEB.** Aspergillosis in hihi (*Notiomystis cincta*) on Mokoia Island. *New Zealand veterinary journal* 47, 88-91, 1999
- Alley MR, Rippon RJ, Castro I.** *Candida* ventriculitis in neonatal hihi chicks (*Notiomystis cincta*). *Kokako* 16, 1, 36, 2009
- Angehr GR.** Ecology and behaviour of the stitchbird with recommendations for management and future research. Department of Internal Affairs, Wellington, New Zealand, 1984
- Armstrong DP, Davidson RS, Dimond WJ, Perrott JK, Castro I, Ewen JG, Griffiths R, Taylor J.** Population dynamics of reintroduced forest birds on New Zealand islands. *Journal of Biogeography* 29, 609-21, 2002
- Armstrong DP, Castro I, Griffiths R.** Using adaptive management to determine requirements of re-introduced populations: The case of the New Zealand hihi. *Journal of Applied Ecology* 44, 953-62, 2007
- Brecht M, Clerihew L, McGuire W.** Prevention and treatment of invasive fungal infection in very low birthweight infants. *Archives of Disease in Childhood - Fetal and Neonatal Edition* 94, 1, F65-F9, 2009
- Buck JD.** A note on the experimental uptake and clearance of *Candida albicans* in a young captive gull (*Larus sp.*). *Mycopathologia* 94, 59-61, 1986
- Cafarchia C, Camarda A, Romito D, Campolo M, Quaglia NC, Tullio D, Otranto D.** Occurrence of yeasts in cloacae of migratory birds. *Mycopathologia* 161, 229-34, 2006
- Castagnola E, Buratti S.** Clinical aspects of invasive candidiasis in paediatric patients. *Drugs* 69, Suppl 1, 45-50, 2009
- Castro I.** Behavioural ecology and management of hihi (*Notiomystis cincta*), an endemic New Zealand honeyeater. Ph.D. Thesis thesis, Massey University, Palmerston North, New Zealand, 1995
- Castro I, Brunton DH, Mason KM, Ebert B, Griffiths R.** Life history traits and food supplementation affect productivity in a translocated population of the endangered hihi (stitchbird, *Notiomystis cincta*). *Biological Conservation* 114, 271-80, 2003
- Concia E, Azzini A, Conti M.** Epidemiology, incidence and risk factors for invasive candidiasis in high-risk patients. *Drugs* 69, Suppl 1, 5-14, 2009
- Craig JL, Stewart AM, Douglas ME.** The foraging of New Zealand honeyeaters. *New Zealand Journal of Zoology* 8, 87-91, 1981
- D'Aloia M, Bailey TA, Samour J, Naldo J, Howlett JC.** Bacterial flora of captive houbara (*Chlamydotis undulata*), kori (*Ardeotis kori*) and rufous-crested (*Eupodotis ruficrista*) bustards. *Avian Pathology* 25, 459-68, 1996
- Dahlhausen RD.** Implications of mycoses in clinical disorders. In: Harrison GJ, Lightfoot TL (eds). *Clinical Avian Medicine*. Pp 691-704. Spix Publishing, Palm Beach, Florida, USA, 2006
- Daszak P, Cunningham AA, Hyatt AD.** Emerging infectious diseases of wildlife: Threats to biodiversity and human health. *Science* 287, 443-9, 2000

- Empson R, Goudswaard R, Booth M.** Report on hihi survival and productivity at Karori Sanctuary, 2008. Unpub. <http://www.hihiconservation.com> (accessed 16/11/2009), 2008
- Empson R, Booth M.** Zealandia - Karori Sanctuary Report to Hihi Recovery Group Meeting April 2009. Unpub. <http://www.hihiconservation.com> (accessed 16/11/2009), 2009
- Friend M.** Candidiasis. In: Friend M, Franson JC (eds). *Field Manual of Wildlife Diseases: General Field Procedures and Diseases of Birds*. Pp 135-6. U.S. Geological Survey, Washington DC, USA, 1999
- Goodenough A, Stallwood B.** Intraspecific variation and interspecific differences in the bacterial and fungal assemblages of Blue Tit (*Cyanistes caeruleus*) and Great Tit (*Parus major*). *Microbial Ecology* 59, 221-32, 2010
- Hazen KC, Howell SA.** *Candida*, *Cryptococcus* and other yeasts of medical importance. In: Murray PR, Baron EJ, Jorgensen JH, Pfaller MA, Tenover FC, Tenover FC (eds). *Manual of Clinical Microbiology*. Pp 1693-711. American Society for Microbiology Press, Washington DC, 2003
- Higgins PJ, Peter JM, Steele WK.** Stitchbird. In: Higgins PJ, Peter JM, Steele WK (eds). *Handbook of Australian, New Zealand and Antarctic Birds. Volume 5: Tyrant-flycatchers to Chats*. Pp 954-66. Oxford University Press, Melbourne, Australia, 2001
- Lovegrove T.** Stitchbirds on Kapiti Island 1983-1985. Department of Lands and Survey, Wellington, New Zealand, 1985
- Low M, Part T, Forslund P.** Age-specific variation in reproduction is largely explained by the timing of territory establishment in the New Zealand stitchbird *Notiomystis cincta*. *Journal of Animal Ecology* 76, 459-70, 2007
- Low M, Part T.** Patterns of mortality for each life-history stage in a population of the endangered New Zealand stitchbird. *Journal of Animal Ecology*, 2009
- Macwhirter P.** Passeriformes. In: Ritchie BW, Harrison GJ, Harrison LR (eds). *Avian Medicine: Principles and Application*. Pp 1172-99. Wingers Publishing, Lake Worth, Florida, USA, 1994
- Nett J, Andes D.** *Candida albicans* biofilm development, modeling a host-pathogen interaction. *Current Opinion in Microbiology* 9, 1-6, 2006
- Oliver WRB.** New Zealand Birds, A.H. & A.W. Reed, Wellington, New Zealand, 1955
- Perrott JK.** Effects of food supply and competition on the outcome of hihi (*Notiomystis cincta*) translocated to Mokoia Island. M.Sc. Thesis thesis, Massey University, Palmerston North, New Zealand, 1997
- Perrott JK.** The ecology of *Aspergillus fumigatus* and implications for wildlife conservation in modified environments. Ph.D. Thesis thesis, Massey University, Palmerston North, 2001
- Quinn PJ, Carter ME, Markey BK, R CG.** Clinical Veterinary Microbiology, Wolfe Publishing, London, UK, 1994
- Rae MA.** The diagnostic value of necropsy. In: Harrison GJ, Lightfoot TL (eds). *Clinical Avian Medicine*. Pp 661-78. Spix Publishing, Palm Beach, Florida, USA, 2006

- Ramage G, Mowat E, Jones B, Williams C, Lopez-Ribot J.** Our current understanding of fungal biofilms. *Clinical Reviews in Microbiology* 35, 4, 340-55, 2009
- Reavill DR, Schmidt RE.** Avian Surgical Pathology. In: Fudge AM (ed) *Laboratory Medicine Avian and Exotic Pets*. Pp 133 - 46. W. B. Saunders Company, Philadelphia, Pennsylvania, USA, 2000
- Sandmeier P, Coutteel P.** Management of canaries, finches and mynahs. In: Harrison GJ, Lightfoot TL (eds). *Clinical Avian Medicine*. Pp 879-914. Spix Publishing, Palm Beach, Florida, USA, 2006
- Shepherd MG, Poulter RTM, Sullivan PA.** *Candida albicans*: Biology, genetics and pathogenicity. *Annual Review of Microbiology* 39, 579-614, 1985
- Taylor S, Castro I.** Hihi standard operating procedures. Unpublished report, Department of Conservation, Wellington, New Zealand, 2000
- Taylor S, Castro I, Griffiths R.** Hihi/Stitchbird (*Notiomystis cincta*) Recovery Plan 2004-2009. Department of Conservation, Wellington, New Zealand, 2005
- Thein Z, Seneviratne C, Samaranayake Y, Samaranayake L.** Community lifestyle of *Candida* in mixed biofilms: a mini review. *Mycoses* 52, 467-75, 2009
- Tompkins DM, Poulin R.** Parasites and biological invasions. In: Allen RB, Lee WG (eds). *Ecological Studies Volume 186: Biological Invasions in New Zealand*. Pp 67-84. Springer-Verlag, Berlin, Germany, 2006
- Tsai SS, Yeh WS, Chi YG, Itakura C.** Force-feeding and candidiasis in pigeons. *Avian Pathology* 23, 569-74, 1994
- Twort FW.** An improved neutral red, light green double stain for staining animals, parasites, micro-organisms and tissues. *Journal of State Medicine* 32, 351, 1924
- Velasco MC.** Candidiasis and cryptococcosis in birds. *Seminars in Avian and Exotic Pet Medicine* 9, 75-81, 2000
- Verran J, Airey P, Packer A, Whitehead K.** Microbial retention on open food contact surfaces and implications for food contamination. *Advances in Applied Microbiology* 64, 223-46, 2008
- Vieira RG, Acqua Coutinho SD.** Phenotypical characterisation of *Candida spp* isolated from crop of parrots (*Amazona spp*). *Pesquisa Veterinaria Brasileira* 29, 452-6, 2009
- Young BJ.** Staining of fungal hyphae in tissue sections. *Journal of Medical Laboratory Technology* 25, 342-6, 1969
- Zhu W, Filler S.** Interactions of *Candida albicans* with epithelial cells. *Cellular Microbiology* 12, 273-82, 2010



## 5 Discussion and conclusions

---

“The role of disease in wildlife conservation has probably been radically underestimated”. This observation by Prof. Aldo Leopold (1933), one of the founding fathers of Conservation Biology, holds true today. Conservation biologists work towards maintaining normal evolutionary processes within functioning ecological systems, and while the focus may be on single-species maintenance and recovery, the health of the ecosystem as a whole will ultimately determine the success or otherwise of such efforts (Meffe et al., 2006). Disease and disease outbreaks are very much interrelated with the dynamics governing ecological systems, since both are reliant on internal factors while subject to impacts from external forces. Maintaining ‘normal’ status requires that all elements continue to interact within the community structures in the face of change, and since the majority of elements involved are dynamic processes (Meffe et al., 2006) this by definition poses more questions than answers. What is ‘normal’, and how does one define and measure the health of an ecosystem that takes into consideration all of the elements within that system in conjunction with the sometimes massive external forces that drive towards change?

The global impact of anthropogenic change continues to evolve at an unprecedented rate and is ongoing, affecting ecosystems at every level. Habitat restoration and wildlife sanctuaries provide a haven for many species under threat and may sustain populations in the wild for the short term, but it is impossible to determine outcomes for the interplay between ecosystem dynamics and evolutionary survival in the long term (Meffe et al., 2006). Surviving endangered species may be the visible indicators of ecosystem health, although it is difficult to measure ecosystem health with any certainty, while the long term effects on population dynamics at the evolutionary scale are impossible to predict. The problem remains, how to achieve the desired result of species preservation without destabilising other relationships within the ecosystem.

Wildlife disease outbreaks often go unrecognised until they reach epidemic proportions within the population or spill-over to affect domestic species or humans (Daszak et al., 2000). By this stage, the impacts of the disease process itself will have changed dynamics within the ecosystem, creating a flow-on effect that further impacts on biodiversity. For species survival, some protection may be required against impacts that

predispose to disease, or that facilitate the spread or increase the virulence of disease causing entities.

The hihi population at Zealandia – Karori Sanctuary (KS) is in the establishment phase; translocated birds may not be well-adapted to the climate or environmental conditions at this site and the reproductive success achieved in the first breeding season has not been repeated over subsequent breeding seasons (Empson and Booth, 2009). The current study has shown that disease-causing organisms can exist within a population in a host-parasite-disease relationship as endemic disease that causes minimal disruption to population dynamics. It was also shown that environmental factors had considerable impact on individual survival of younger nestlings; this may flow-on to affect the population as a whole. Further, a combination of ecological impacts and opportunistic pathogens caused deaths in older nestlings that may also impact on population numbers over time.

Peak physical condition and fast physiological responses are prerequisites for a long and healthy life in free-living species and any factor that impacts on the fright, flight, and fight response frequently has disastrous consequences. Impacts on survival may be hidden if decreased fitness and sub-clinical illness occurs rather than mortality. However, the impact on population viability may well be the same. Parasite infestations may impact on fitness levels leaving the host more vulnerable to predation or disease, and less able to survive in the wild. Low numbers of ectoparasites, in particular nest mites including the tropical fowl mite (*Ornithonyssus bursa*) were present at KS and the numbers may be sufficient to cause reduced fitness in nestlings without clinical manifestations (A. Heath, pers. comm.). It is also possible that ectoparasite numbers will build up over time at this site to approach the levels seen at Tiritiri Matangi and Mokoia islands and if so this will require more active management to reduce nestling mortality.

The nest boxes currently in use at KS may not provide adequate protection for survival of nestlings <8 days old. Minimum daily temperatures at KS are lower than hihi experience on Hauturu or Tiritiri Matangi islands and confirmation of the impact external temperature fluctuations have on the nest box microclimate is needed. Insulation may need to be incorporated into the KS nest boxes to improve nestling survival at this site. Alternatively, it may be possible to introduce heating pads to some nests when inclement weather is predicted although the risk of dehydration or thermal burns in featherless nestlings must be considered. Small (<5°C) increases in nest temperature in temperate climates improves nestling survival and growth rates (Dawson et al., 2005) and may also prevent



depletion of subcutaneous fat reserves (Ardia, 2005). If such measures prove to be successful, they may improve fitness in nestlings and provide a management tool to boost productivity at other sites, thus providing founder birds for future translocations.

The mammalian-predator-proof fence that excludes predators does not impede the movement of flighted avian species which may travel freely beyond the perimeter of the sanctuary. It also means that birds from outside the sanctuary are readily able to access food sources and habitat within the sanctuary, transporting parasites and pathogens as they do so. The risk of a catastrophic disease outbreak increases when novel parasites and pathogens are introduced to previously unexposed populations, such as hihi originating from the closed populations on Hauturu and Tiritiri Matangi islands.

*Candida albicans* was associated with mortality events in hihi nestlings at KS, and carriage and colonisation or disease establishment in nestlings may be facilitated by sugar-water provisioning. Adult carriers accessing feeders may pass the organism as well as the means for rapid colonial growth (carbohydrates) to the nestlings they are provisioning. During the study period, hihi at KS were subject to a provisioning experiment and sugar-water and Wombaroo™ Insectivore mix were provided at opposite ends of the valley (Empson and Booth, 2009). Both Wombaroo™ and sugar-water have high carbohydrate content, but the former represents a more complex and complete food source. Managers at KS hope to establish whether changing the provisioning protocols impacts on nestling gender and gender survival rates (Empson and Booth, 2009). This experiment could also have been included into the present study, but it was not possible to establish relationships between provisioning treatments and *Candida albicans* infection of the nestlings. The parent birds from the affected nests visited sugar-water feeders but the very small sample size did not allow a statistical significance to be estimated. This would be an interesting and perhaps very important future study should *Candida albicans* prove to be an emerging pathogen at this site.

Staff and volunteers responsible for provisioning and feeder maintenance at KS follow strict hygiene protocols. Feeders are cleaned and the substrate replaced every second day (Taylor and Castro, 2000). Different carbohydrate substrates (sugar-water or Wombaroo™) were fed at opposite ends of the valley. While the feeders and substrates at KS were not sampled or cultured, there was no evidence from Mokoia, using the same foods and cleaning protocols (Taylor and Castro, 2000), that feeders or feedstuffs were the source of *Candida albicans* in that population. The rigorous hygiene protocols in place at KS suggest it is unlikely that *Candida spp* would proliferate and attain high levels of

contamination. It was considered that feed contamination issues would be detected by oral swabs as nestlings would show evidence of transient colonisation. There was no evidence of *Candida spp* in swabs taken from the majority of nestlings. Nestlings in which *Candida albicans* was detected showed evidence of gastrointestinal tract colonisation. Once detected, *Candida albicans* continued to be isolated from oral and faecal or cloacal swabs at subsequent sampling times. *Candida albicans* was seen to affect all siblings within each of the affected nests and at one of the nests, the female parent was also infected by *Candida albicans*. All of the colonised nestlings that died were shown to have evidence of candidiasis on histology. While much more work undoubtedly needs to be done to confirm these preliminary findings, this study suggests vertical transmission from parent to offspring may occur. A comprehensive study would possibly include culturing the substrates and feeder surfaces, as well as collecting gastrointestinal swabs from the parent birds. It would be interesting to determine whether colonised nestlings that survived to fledge remained colonised, and whether as parents they disseminate *Candida albicans* to their offspring.

Exposure to environmental spores of *Aspergillus fumigatus* causes respiratory disease in many species (Perrott, 2001). A single nestling was found to have died from aspergillosis during this study but mortality associated with this disease may be quite high overall because adult birds are most often affected (Alley et al., 1999). Aspergillosis is associated with highly modified habitat in New Zealand and very high spore levels found at some translocation sites contribute to disease manifestation in hihi (Perrott, 2001). As an example, habitat at Mokoia Island proved to be unsuitable for hihi establishment because high spore counts equated to high mortality rates that limited the adult population (Armstrong et al., 2007). The impact of aspergillosis together with other diseases and native predators such as the morepork (*Ninox novaeseelandiae*) may, in a small population such as the one at KS, cause high mortality resulting in low population viability, or even extinction of the local population. The habitat at KS is highly modified and may show elevated spore counts; therefore it would be prudent to undertake environmental spore monitoring at this site and to continue to monitor the incidence of morbidity and mortality due to aspergillosis.

Cause of death for one nestling was attributed to an unidentified haemoparasite suggesting that the parasite exists within the avian population at KS and that there is also a corresponding vector present. Avian malaria caused by *Plasmodium spp* relies on mosquitoes for carriage, but other haemoparasites are associated with different vectors. While it is now becoming apparent that some endemic birds in New Zealand may have

evolved with endemic haemoparasites with little or no clinical effects (Tompkins et al., unpub; Castro et al., unpub.), it is also known that in naive species haemoparasites may cause rapid population declines (van Riper III et al., 1986). Clinical manifestation in naive species may differ markedly from the known clinical picture seen to be associated with disease in host species (Pierce, 2000). This may be because naive species have no innate immunity to novel parasites and therefore succumb to disease very rapidly. Penguins infected by *Plasmodium spp* may die from damage caused by schizonts in tissue phase only without any detectable presence in the erythrocytes (Pierce, 2000). Recovery of dead birds for necropsy and histological tissue examination will be necessary to determine whether this is also true for hihi.

Some hihi parents feed introduced bees and wasps to their offspring and this proved to be detrimental to the health of nestlings at KS. Hihi may lack the evolutionary skills and adaptations necessary to safely utilise these invertebrates. Sting penetration caused traumatic ventriculitis lesions and the resulting granulomas were often colonised by opportunistic pathogens from the gastrointestinal tract of the nestlings. Traumatic ventriculitis was associated with high mortality rates among the affected nestlings but it was not possible to determine the long term impacts on population viability. Foraging studies may be required to establish the prevalence of this phenomenon at both this and other sites. Reducing the habitat overlap between these species may necessitate altering the provisioning protocols at translocation sites, as bees and wasps are attracted to sugar-water feeders which are used to supplement the hihi diet.

In the absence of mortality events and where recovery of dead birds is problematic, health parameters in live birds may provide insight into the physical condition and fitness of the population. This study showed that PCV was not related to body condition in hihi nestlings, but that PCV values were correlated within specific nests and with clutch order, suggesting parental fitness and parenting skills were factors influencing PCV. In a study of captive adult Northern bald ibis (*Geronticus eremita*) in Spain, it was shown that trends in PCV correlated positively with trends in plasma cholesterol and that PCV was also positively correlated with subcutaneous fat reserves (Sanchez-Guzman et al., 2004). It was noted that the plasma collected from hihi nestlings at KS was often noticeably lipaemic. If this were proven to be the result of high levels of plasma cholesterol in these nestlings, then this may become a useful indicator of body fat stores in live nestlings. Body fat levels have been used as an indicator of fitness and it is thought that increased levels at fledging are a positive indicator of survival through to recruitment (Ardia, 2005, Sanchez-Guzman et al., 2004). It would be useful to follow up on these preliminary

findings in hihi nestlings, as there are currently very few indicators of health established for live hihi.

This study was limited to a very short period of time, i.e. a single breeding season, and the numbers of nestlings sampled was relatively small. No evidence was found of coccidia or other gastrointestinal ova, cysts or parasites. The nestling hihi population at KS showed no clinical evidence of viral disease and, while histological examination provides a poor indicator of viral disease in many cases, no evidence of viral infection was seen in the dead nestlings submitted for necropsy. Over time, it is likely that those parasites and pathogens currently known to be affecting the population may change in status and that other disease causing entities will emerge to impact on this population. It was apparent that environmental conditions were important factors limiting nestling survival at this site and this is also likely to be true for establishing hihi populations at other sites. The remnant hihi population on Hauturu still remains the only self-sustaining population for this species and while the populations on Tiritiri Matangi and Kapiti islands are successful under management, all other translocated populations have yet to prove they are viable. Conservation biology is an exercise in crisis management and as such requires a multidisciplinary approach to resolve the many faceted aspects of species survival (Meffe et al., 2006). It becomes increasingly important to know what factors affect population survival and why, so that future translocations may be targeted towards sites that are favourable for the establishment and long term viability of hihi. Only in this way will populations of this species survive for future generations to enjoy.

## References

- ALLEY, M. R., CASTRO, I. & HUNTER, J. E. B. (1999) Aspergillosis in hihi (*Notiomystis cincta*) on Mokoia Island. *New Zealand Veterinary Journal*, 47, 88-91.
- ARDIA, D. R. (2005) Super size me: an experimental test of the factors affecting lipid content and the ability of residual body mass to predict lipid stores in nestling European starlings. *Functional Ecology*, 19, 414-20.
- ARMSTRONG, D. P., CASTRO, I. & GRIFFITHS, R. (2007) Using adaptive management to determine requirements of re-introduced populations: The case of the New Zealand hihi. *Journal of Applied Ecology*, 44, 953-62.
- DASZAK, P., CUNNINGHAM, A. A. & HYATT, A. D. (2000) Emerging infectious diseases of wildlife: Threats to biodiversity and human health. *Science*, 287, 443-9.
- DAWSON, R. D., LAWRIE, C. C. & O'BRIEN, E. L. (2005) The importance of microclimate variation in determining size, growth and survival of avian offspring: experimental evidence from a cavity nesting passerine. *Oecologia*, 144, 499-507.
- EMPSON, R. & BOOTH, M. (2009) Zealandia - Karori Sanctuary Report to Hihi Recovery Group Meeting April 2009. Unpub. <http://www.hihiconservation.com> (accessed 16/11/2009).
- MEFFE, G. K., CARROLL, C. R. & GROOM, M. J. (2006) What is conservation biology? IN GROOM, M. J., MEFFE, G. K. & CARROLL, C. R. (Eds.) *Principles of Conservation Biology, 3rd Edition*. Sunderland, MA, USA, Sinauer Associates, Inc.
- PERROTT, J. K. (2001) The ecology of *Aspergillus fumigatus* and implications for wildlife conservation in modified environments. *Wildlife Ecology*. Palmerston North, Massey University.
- PIERCE, M. A. (2000) Hematozoa. IN SAMOUR, J. (Ed.) *Avian Medicine*. London, UK, Mosby Publishers.
- SANCHEZ-GUZMAN, J. L., VILLEGAS, A., CORBACHO, C., MORAN, R., MARZAL, A. & REAL, R. (2004) Response of the haematocrit to body condition changes in Northern bald ibis *Geronticus eremita*. *Comparative Biochemistry and Physiology, Part A*, 139, 41-7.
- TAYLOR, S. & CASTRO, I. (2000) Hihi standard operating procedures. Wellington, New Zealand, Unpublished report, Department of Conservation.
- VAN RIPER III, C., VAN RIPER, S. G., GOFF, M. L. & LAIRD, M. (1986) The epizootiology and ecological significance of malaria in Hawaiian land birds. *Ecological Monographs*, 56, 327-44.